HAL
open science

Rodent models used in preclinical studies of deep brain stimulation to rescue memory deficits

Matthieu Faillot, Antoine Chaillet, Stéphane Palfi, Suhan Senova

To cite this version:

Matthieu Faillot, Antoine Chaillet, Stéphane Palfi, Suhan Senova. Rodent models used in preclinical studies of deep brain stimulation to rescue memory deficits. Neuroscience and Biobehavioral Reviews, 2021, 130, pp.410-432. 10.1016/j.neubiorev.2021.08.012 . hal-03520529

HAL Id: hal-03520529

https://centralesupelec.hal.science/hal-03520529

Submitted on 16 Oct 2023

HAL is a multi-disciplinary open access archive for the deposit and dissemination of scientific research documents, whether they are published or not. The documents may come from teaching and research institutions in France or abroad, or from public or private research centers.

L'archive ouverte pluridisciplinaire **HAL**, est destinée au dépôt et à la diffusion de documents scientifiques de niveau recherche, publiés ou non, émanant des établissements d'enseignement et de recherche français ou étrangers, des laboratoires publics ou privés.

Distributed under a Creative Commons Attribution - NonCommercial 4.0 International License

Version of Record: https://www.sciencedirect.com/science/article/pii/S0149763421003559
Manuscript_382192a7364e1ee4ad246b55596fb707

Title page:

Title: Rodent models used in preclinical studies of deep brain stimulation to rescue memory deficits

Author names and affiliations :

Matthieu Faillot [1]: Neurosurgery department, Henri Mondor University Hospital, APHP ; Mondor Institute for Biomedical Research, INSERM U955, Team 15, Translational Neuropsychiatry

Antoine Chaillet: Laboratoire des Signaux et Systèmes (L2S-UMR8506) - CentraleSupélec – Université Paris Saclay – Institut Universitaire de France

Stéphane Palfi : Neurosurgery department, Henri Mondor University Hospital, APHP ; Mondor Institute for Biomedical Research, INSERM U955, Team 15, Translational Neuropsychiatry

Suhan Senova : Neurosurgery department, Henri Mondor University Hospital, APHP ; Mondor Institute for Biomedical Research, INSERM U955, Team 15, Translational Neuropsychiatry

Corresponding author: Dr Suhan Senova, Service de Neurochirurgie, Hôpital Henri Mondor, 51 avenue du Maréchal de Lattre de Tassigny, 94000 Créteil, yann.senova@aphp.fr

Highlights:

- DBS is a promising treatment for memory deficits of patients with TBI and stroke.
- Proof of concept studies in rodent models of TBI and stroke are needed.
- High heterogeneity is observed among models, which mirrors the clinical variability.
- We review the histological, behavioral and electrophysiological findings observed in each model
- We propose a translational framework to assess the efficacy of DBS in rodent models.

Declarations of interest: none.
Funding sources: Matthieu Faillot received a grant from Assistance Publique Hôpitaux de Paris (APHP).

[1] Present address : Neurosurgery department, Beaujon University Hospital, APHP

© 2021 published by Elsevier. This manuscript is made available under the CC BY NC user license
https://creativecommons.org/licenses/by-nc/4.0/

Keywords : Traumatic Brain Injury, Stroke, Rodent, Deep Brain Stimulation, Memory

Abbreviations :
2VO : Two- vessels occlusion ;
4-VO : Four-vessels occlusion ;
APP : amyloid precursor protein ;
atm : Atmosphere ;
AMPA : alpha-amino-3-hydroxy-5-methyl-4-isoxazolepropionic acid ;
BCAO : Bilateral Carotid Artery Occlusion ;
BCAS : Bilateral Carotid Artery Stenosis ;
BOLD : Blood-Oxygen-Level Dependent ;
CA1 (2,3,4) : Cornu Ammonis 1 (2, 3, 4) ;
CCI :controlled cortical impact ;
ChAT : choline acetyltransferase ;
DAPI : 4',6-diamidino-2-phenylindole ;
DBS : deep brain stimulation ;
DG : dentate gyrus ;
dMRI : diffusion MRI ;
DTI : Diffusion Tensor Imaging ;
ET-1 : endothelin 1 ;
EEG : electroencephalogram ;
FA : Fractional Anisotropy ;
fMRI : functional MRI ;
FST : Forced SwimTest ;
GABA : gamma-aminobutyric acid ;
GAD : glutamic acid decarboxylase ;
HE : Hematoxylin Eosin ;
Hz : Hertz ;
LFP : local field potentials ;
LTP : long term potentiation ;
MAP-2 : microtubule associated protein 2 ;
MCA : Middle Cerebral Artery ;
MCAO : Middle Cerebral Artery Occlusion ;
MEMRI : Manganese Enhanced MRI ;
MIMO : Multi-input Multi-Output
MMSE: Mini Mental State Examination ;
MOCA: Montreal Cognitive Assessment ;
mPFC : medial Prefrontal Cortex ;
MRI : magnetic resonance imaging ;
MS : medial septum ;
MWM : Morris Water Maze ;
NMDA : N-methyl-D-aspartate ;
PAC : phase amplitude coupling ;
PAT : Passive Avoidance Task ;
PET : Positron Emission Tomography ;
psi : pound per square inch ;
PTSD : post traumatic stress disorder ;
PV+ : paravalbumine positive ;

SOM+ : somatostatin positive ;
SWR : sharp wave ripples ;
TBI : traumatic brain injury ;
TST : tail suspension test ;
VPL Th: ventro posterolateral thalamus ;

1. Introduction 9
2. Traumatic Brain injury (TBI) 12
2.1. Clinical aspects 12
2.2 Available models 12
2.2.1. Open-skull models: controlled cortical impact and fluid percussion 13
2.2.1.1. Histology 13
2.2.1.1.1. Cortex 13
2.2.1.1.2. Hippocampus 14
2.2.1.1.3. Other subcortical structures 15
2.2.1.1.4. Contralateral hemisphere 16
2.2.1.2. Behavior 16
2.2.1.2.1. Memory impairments: 16
2.2.1.2.2. Motor impairment and locomotion 17
2.2.1.2.3. Sensory impairments 17
2.2.1.2.4 Anxiety and depression 18
2.2.1.3. Electrophysiology 18
2.2.1.3.1. Cortical activity: 18
2.2.1.3.2. Excitability and Long-term potentiation in the hippocampus: 19
2.2.1.3.3. Epilepsy 20
2.2.1.3.4. Neuromodulation: 20
2.2.2. Closed-skull models: weight drop, impact acceleration and blast 20
2.2.2.1. Histology 21
2.2.2.1.1. Cortex 21
2.2.2.1.2. Hippocampus 22
2.2.2.1.3. Other subcortical structures 22
2.2.2.2. Behavior 23
2.2.2.2.1. Memory 23
2.2.2.2.2. Motor impairment and locomotion 24
2.2.2.2.3. Sensory impairments 24
2.2.2.2.4. Anxiety and depression 25
2.2.2.3. Electrophysiology 25
2.2.2.3.1 Cortical activity 25
2.2.2.3.2 Excitability and long-term potentiation in the hippocampus 26
2.2.2.3.3 Epilepsy 26
2.2.2.3.4 Other 26
2.2.2.3.5 Neuromodulation 26
2.3 Provisional summary: TBI models 26
3. Rodent models of stroke and vascular cognitive impairment 28
3.1. Clinical features 28
3.2. Available models 29
3.2.1. Focal cerebral ischemia 29
3.2.1.1. Histology 30
3.2.1.1.1. Cortex 30
3.2.1.1.2. Hippocampus and subcortical structures 30
3.2.1.1.3. Lesions outside the ischemic territory 31
3.2.1.2. Behavior 31
3.2.1.2.1. Memory 31
3.2.1.2.2. Sensorimotor impairment 32
3.2.1.2.3. Sensory impairment 33

3.2.1.2.4. Neuropsychiatry 33
3.2.1.3. Electrophysiology 34
3.2.1.3.1. Cortical activity 34
3.2.1.3.2. Excitability and Long-Term Potentiation in the hippocampus 35
3.2.1.3.3. Epilepsy 35
3.2.1.3.4. Other 35
3.2.1.3.5. Neuromodulation 35
3.2.2. Global ischemia 36
3.2.2.1. Histology 37
3.2.2.1.1. Cortex 37
3.2.2.1.2. Hippocampus and other subcortical structures 37
3.2.2.2. Behavior 38
3.2.2.2.1. Memory 38
3.2.2.2.2. Motor impairment 39
3.2.2.2.3. Sensory impairment 39
3.2.2.2.4 Neuropsychiatry 39
3.2.2.3. Electrophysiology 40
3.2.2.3.1. Cortical activity 40
3.2.2.3.2. Excitability and Long-Term Potentiation in the hippocampus 40
3.2.2.3.3. Epilepsy 41
3.2.2.3.4. Neuromodulation 42
3.3. Provisional summary: ischemia models 42
4. Discussion 44
4.1. Hippocampal dysfunction 44
4.2. Beyond the hippocampus 44
4.3. Shift in the excitatory and inhibitory balance 44
4.4. Possible role of long-range synchrony and relation to structural lesions 45
4.5 Restoring theta-gamma phase amplitude coupling 45
4.6. Which structure(s) to target? 46
4.7. Other challenges 47
4.8. Limitations of this review 48
5. Conclusions 48

Abstract

FAILLOT, M., A. CHAILLET, S. PALFI and S. SENOVA.

Rodent models used in preclinical studies of deep brain stimulation to rescue memory deficits...NEUROSCI BIOBEHAV REV 21(1) XXX-XXX, YEAR.-

Deep brain stimulation paradigms might be used to treat memory disorders in patients with stroke or traumatic brain injury. However, proof of concept studies in animal models are needed before clinical translation. We propose here a comprehensive review of rodent models for Traumatic Brain Injury and Stroke. We systematically review the histological, behavioral and electrophysiological features of each model and identify those that are the most relevant for translational research.

[70 words]

1. Introduction

Neurosurgeons who were implanting electrodes in the posterior hypothalamus serendipitously discovered that open-loop deep brain stimulation (DBS) of the fornix acutely improved autobiographical memory [1]. However in a phase II forniceal DBS trial there was only a trend towards improvement in memory scores for a subgroup of patients with Alzheimer's disease (AD) (>65 years old) [2]. The same study showed an increase in glucose metabolism using positron emission tomography (PET). Studies investigating chronic DBS of the nucleus basalis of Meynert to treat memory disorders in patients with AD [3], Parkinson's disease dementia [4] and Lewy body dementia [5 6] found little (reduction in complex visual hallucinations [4] in some patients, stability of cognitive scores in some patients [3]) or no benefit [6]. Other groups performed acute stimulation experiments in epileptic patients implanted with intracranial electrodes (as part of a diagnostic presurgical evaluation). Electrical stimulation of the entorhinal area [7 8 9 10], hippocampus [7 8 11 12 13 14 15,16], amygdala [17], lateral temporal cortex [18,19], fornix [20,21], frontal cortex [22] , and posterior cingulate cortex [23] have been investigated. These studies have produced conflicting results with either improvement or worsening of performance in memory tasks. As reviewed in [24], a potential explanation for these conflicting results is the high variability regarding the stimulation paradigms (design of electrodes, current shape and intensity). Recently, investigators successfully implemented acute closed-loop stimulation paradigms (lateral temporal cortex stimulation upon the identification of poor memory encoding biomarker [18,19], patterned Cornu Ammonis 1 (CA1) stimulation based on a multi-input multi-output (MIMO) model which predicts optimal CA1 output based on Cornu Ammonis 3 (CA3) recordings [16]. Before clinical translation to treat memory disorders, DBS needs to be investigated in preclinical models. Other neurological diseases associated with less diffuse neuronal damages than AD, such as traumatic brain injury (TBI) or stroke, would also deserve preclinical investigations.

Preclinical models are useful to investigate the effect mechanisms of DBS. Studies performed using preclinical models of AD [25 26 27] and Rett syndrome [28] have reported memory improvements and increased neurogenesis, synaptic markers and trophic factor expression following chronic DBS of the fornix [28 26 27] or entorhinal cortex [25 27 29].Synaptic function has been proposed to be a target of neuromodulatory strategies and can be studied extensively in rodents using microscopy and electrophysiology. Pre-clinical models would also be ideal to investigate closed-loop stimulation strategies. These strategies could allow researchers to

adapt the stimulation to the ongoing brain activity (encoding versus retrieval of information). This would build upon decades of work where neuroscientists have been able to correlate dynamics of brain oscillations to behavior of rodents [30]. The theta rhythm (a slow frequency oscillation that propagates across structures) is associated to a variety of behaviors. For example during spatial navigation in rodents place cells fire at specific phases of the theta rhythm [31]. Amplitude of the gamma rhythm (>30 Hz) fluctuates according to the phase of the theta rhythm, a phenomenon called phase-amplitude coupling. In CA1, fast gamma activity is maximal at the through of the theta cycle during encoding, while slow gamma activity is maximal at the peak of the theta phase upon retrieval[32] [33].

However, translation from pre-clinical models remains a challenge. This is particularly the case for TBI and stroke [34] which encompass a large clinical spectrum and can affect a variety of neuroanatomical structures. It is for instance hard to determine if one preclinical model corresponds to a minor or a major form of the human disease [35] [36]. Studying cognitive function represents an additional challenge since deficits can be observed in multiple domains (attention and memory, for instance) which might be challenging to disentangle in rodents.

The goal of this review is thus to provide a comprehensive description of rodent models for TBI and stroke, enabling researchers to choose the most relevant preclinical models from a clinical point of view, particularly in terms of potential DBS-induced therapeutic mechanisms.

From this translational perspective, we will briefly describe how memory is affected in patients and present the different available rodent models for each pathological condition (TBI and stroke). We searched for rodent studies on PubMed using the keywords “Traumatic Brain Injury”, “TBI”, “Fluid Percussion Injury”, “Lateral Fluid Percussion”, “Controlled Cortical Impact”, “Weight Drop”, “Impact-Acceleration”, “Blast”, “Stroke”, “Ischemia”, “Vascular Dementia”, “Vascular Cognitive Impairment”, “Middle Cerebral Artery Occlusion”, and “Cardiac Arrest”. We focused on studies assessing histological damage, behavior, and electrophysiological correlates of memory disorders.

We will review the histological (figure 2 and supplementary tables), electrophysiological (table 1 and supplementary tables) and behavioral features (figure 3 and supplementary tables) of each model, as well as results of neuromodulation studies.

In the final conclusions, we will discuss the potentially most relevant models for closed-loop DBS investigations.

2. Traumatic Brain injury (TBI)

2.1. Clinical aspects

Patients with TBI [37] [38] [39] [40], including mild TBI [40] [41], display memory disorders (working memory and long-term memory, including episodic memory) as well as other cognitive deficits (attention deficits, mental fatigue, reduced speed of processing, executive disorders, lack of awareness) and neuropsychiatric disorders.

The outcomes are difficult to predict after TBI because patients are heterogeneous in terms of the mechanism of injury as well as brain regions and networks affected. Atrophy of the hippocampus and mesiotemporal structures is associated with cognitive deficits after trauma [42] [43], although this finding is controversial [44] [45]. Other lesions associated with cognitive deficits include diffuse axonal injury with white matter lesions [46] [47] [48] (particularly in the fornix [43], deep white matter tracts [49] and thalamocortical fibers [50]). Evidence has been reported [51] of impaired functional connectivity in both externally oriented networks (frontoparietal attentional network and executive central network) and internally oriented networks (such as the default mode network that includes the mesiotemporal structures, the posterior cingulate and the angular gyrus). A decrease in interhemispheric connectivity has been observed, along with an increase in intrahemispheric connectivity, but researchers are still debating whether these changes in connectivity are detrimental or related to compensatory mechanisms [52].

2.2 Available models

TBI models can be classified in two main classes. Open-skull TBI models correspond to focal lesions induced using methods such as controlled cortical impact (CCI) and fluid percussion injury (FPI). Closed-skull models provoke more diffuse lesions, such as the impact acceleration model and the weight drop model. The validity of the distinction between focal and diffuse models is questionable, since models of focal injury tend to produce lesions

remote to the site of injury. Both these classes are described below, together with blast models, which are especially relevant to military injuries.

Both open-skull and closed-skull TBI models produce extensive neuronal loss (principal cells and interneurons) in the cortex and in the hippocampus, predominating in the CA3 subfield. Extensive degeneration has been observed in the cortex, the hippocampus as well as a variety of subcortical structures, including white matter bundles, which are particularly affected in closed-skull models. There is electrophysiological evidence for impaired long-term potentiation in the hippocampus in both kind of models. However, changes have been observed at the whole-brain scale with early hypoactivity followed by late hyper-activity, as well as disturbed long-range synchronies. Overall, histological and electrophysiological data suggest interneuronal loss and synaptic dysfunction in cortex and hippocampus. This might account for the enduring spatial memory deficits which have been observed in behavioral experiments. DBS has been proven beneficial in open-skull models. Models of blast injury seem to stand apart with specific involvement of amygdala, increased fear memory, and increased theta-gamma cross frequency coupling in prefrontal cortex.

2.2.1. Open-skull models: controlled cortical impact and fluid percussion

CCI is an open-skull model that mimics brain contusions when applying a force transmitted to the brain of the head-fixed animal via an impactor tip positioned against the dura exposed after a craniotomy [53] (figure 1). The key advantage of this model is that the biomechanical characteristics of the force, which is produced by an electromagnetic or pneumatic device, can be finely tuned and reproduced. Variations in the displacement of the impactor tip [54 55] (which must be adapted to the size and age of the animal and ranges from 0.5 mm to 3 mm in rodents [56]) and in the speed, position [56], size and shape (flat and beveled impactors are associated with worse lesions [57]) of the impactor are directly related to the severity of brain lesions. Mortality is very low [56] when reported.

FPI, another open-skull model, consists in using a pendulum to apply a pressure force to a water column connected to the brain through a Leuer-Lock catheter placed in the epidural space (figure 1). The compression force is measured with an oscillometer connected to the water column. The severity of the injury depends on the applied pressure and on the position of the impact [58] . Medial and anterior sites of impact are associated with bilateral

and deep brain injuries. A higher mortality rate is observed in the FPI model than in the CCI model [59], with up to 50 to 60% mortality observed in the most severely injured groups [60].

2.2.1.1. Histology

2.2.1.1.1. Cortex

In both models, histological examinations of the rodent brain showed lesions in the cortex underlying the impact. In CCI [61] and FPI [62] models, these lesions lead to the formation of a cavity bordered by gliosis within four days and two weeks, respectively. Over a year, a loss of cortical volume manifested as the cavity increased in size [63]. However, in rodents with mild FPI (0.5-1.2 atm), the brain could appear normal upon gross examination, while a microscopic analysis could show evidence of cell loss [64]. Cortical damage involved the sensorimotor cortex underlying the impact site, as well as the adjacent cortex, including the posterior parietal cortex [65].

Cell-loss

There is evidence for cell-loss at the impact site, affecting mainly the inhibitory parvalbumin-positive and somatostatin-positive interneurons [66]

Neuroinflammation and neurodegeneration

There is evidence of neurodegeneration [67] [61], neuroinflammation [61] at the impact site. Damage also extended to the entorhinal cortex [68] and medial prefrontal cortex, which showed neuroinflammation along with glial cell infiltration, as evidenced by GFAP staining [69], causing researchers to question the focal nature of these models.

2.2.1.1.2. *Hippocampus*

Cell-loss

In CCI [70] [71] [72] [73] and FPI models [74] [64] [65], neuronal loss predominated in the dentate gyrus (DG) and CA3 region, with a loss of synaptic projections from CA3 to CA1. Cell loss in the DG affected GABAergic interneurons (see below) as well as mossy cells and has been observed for up to one year [63]. CA3 cell loss has been reported to peak at day 1 [72]. CA1 neuronal loss has also been observed in animals with severe lesions after CCI [71] [61] [75] and FPI [64]. In both models, the location and extent of neuronal loss depended on the intensity and trajectory of the impact force [76], with trajectories parallel to the midline producing more damage in CA1

[64].

Interneuron loss, which has been observed at one week [77] [78] and up to six months after trauma [79], has been the focus of many investigations. Losses of GABAergic interneurons and glutamatergic interneurons (mossy cells) have been observed in the DG [78]. Although the granule cell layer is affected, a preferential loss of interneurons whose somata are located in the hilus has been observed [76] [78]. The lack of a laminar structure in the hilus possibly rendered these interneurons more susceptible to physical deformation [78]. Interneuron loss has also been observed in CA1 [77] [76] and to a lesser extent in CA3 [76]. It included GABAergic interneurons that inhibit the soma of principal cells and granule cells (parvalbumin- [80] [76] [78] [79] and cholecystokinin-positive [78] [79] interneurons) and interneurons responsible for dendritic inhibition (somatostatin- [76] [79], calretinin- [76] [79] and neuropeptide Y-positive [79] interneurons).

Neurodegeneration and neuroinflammation

Neurodegeneration has also been observed but might be underappreciated with conventional histological techniques. Fluoro-Jade staining showed degenerating cell bodies in the DG, CA3 and to a lesser extent, CA1 [81] [71] [82], but these changes tended to decrease after day 1 [71], although they were still observed seven days after injury in both hemispheres [67]. Axonal and dendritic degeneration might be better assessed with silver impregnation techniques, which showed degenerating axons in the stratum oriens of CA1 and damage to dendrites and the Schaffer collateral projections in the CA3 stratum radiatum [81]. Other researchers [83] have highlighted the use of Timm staining [84], another silver staining method, to show mossy fiber sprouting in the DG. This phenomenon, which corresponds to new connections between mossy fibers and the dendritic field of granule cells (as well as inhibitory interneurons), is thought to increase network excitability and might be associated with posttraumatic epilepsy [85]. Hippocampal neuroinflammation with glial cell infiltration has been observed in animal models of CCI [86] and FPI injury [87] [88].

In animals with FPI injury, MRI examination revealed abnormal diffusion values in the hippocampus when measured three weeks after injury [89].

2.2.1.1.3. Other subcortical structures

Cell-loss

A decrease in the number of cholinergic neurons [90] and ongoing atrophy have been observed in the medial septal nucleus one month and one year after FPI, respectively [74] .

Neurodegeneration and neuroinflammation

Damage is diffuse in both models. Degeneration has been observed in the thalamus within the first week after injury [91] and up to one year after injury, as evidenced by calcifications [63], axonal swelling and immunoreactivity for amyloid precursor protein (APP) [62]. Neuroinflammation [61] and an increased blood vessel density [92] have also been described. Similar patterns of neurodegeneration have been observed in the striatum [67] [62], hypothalamus [81] and cerebellum [67].

Ventricular enlargement has been proposed to be a consequence of white matter damage [93] [88] [94], which has been observed directly with stains assessing myelin loss [95] or necrosis [96] [97] as well as MRI imaging [98], providing evidence for white matter tears "in the fimbria, the corpus callosum and in the alveus" [89]. Moreover, one study using the Palmgren silver staining technique did not obtain evidence of neurodegeneration in the fimbria four weeks after FPI [99]. Brainstem lesions are not a common feature of these models but have been observed in some models of FPI when the craniotomy is located close to the midline [60].

2.2.1.1.4. Contralateral hemisphere

Little direct damage to the contralateral hemisphere has been observed. However, studies using Fluoro-JadeB and/or amino-cupric silver staining in animals subjected to CCI [81] and FPI [67] showed that degeneration can extend to the contralateral hemisphere, although this change was not observed four weeks after FPI using the Palmgren silver staining technique [99].

2.2.1.2. Behavior

2.2.1.2.1. Memory impairments:

Anterograde memory:

Deficits in anterograde memory have been observed in animal models of FPI [100] and CCI injury [101], with injured animals displaying a longer latency to learn the location of the hidden platform in the MWM [62] [102]. Similar deficits have also been observed in the Barnes maze [103] [104] [105] and object recognition tasks [106]. These deficits in anterograde memory appeared to depend on the hippocampus, since animals did not display impairments in the constant-start

version of the MWM [107]. Importantly, craniectomy in itself has been associated to deficits in object recognition tasks [108]. A deficit in the fear response has been observed 1 week after injury [109].

Retrograde memory:

Retrograde memory was impaired two days after FPI, with deficits in reference memory in the MWM when animals were trained two hours before injury [110]. Retrograde memory was also impaired at two weeks in animals trained either one day or two weeks before injury [111]. In the latter group, these deficits appeared to improve with a reminding procedure, suggesting retrieval deficits [111]. Retrograde memory was also impaired in animals subjected to CCI and assessed using the passive avoidance task [77].

Working memory:

Deficits in working memory have been observed in the radial maze, as measured by the number of entries into a previously explored arm [99], and in the MWM, where investigators measured the ability of the rat to remember the position of the hidden platform in two consecutive trials [112]. Spontaneous alternation in the T-maze [69 113] and swim T-maze [114] was also impaired.

Cognitive flexibility:

An impairment in reversal learning was observed in rat pups with CCI injury at postnatal day 12 and was assessed using a visual discrimination task in a touchscreen conditioning box between postnatal day 45 and postnatal day 90 [98]. Reversal learning has also been assessed using the MWM [115 116], where the location of the platform was moved after initial learning to evaluate cognitive flexibility.

Behavioral deficits tended to persist in the long term. Deficits in the MWM have been observed at seven months [92] and up to one year [62] after FPI injury, with impaired learning of the task in injured animals (but no difference in the probe trial). However, this finding has been observed in the most severely injured animals [117]. Deficits in working memory have been observed up to four months after CCI injury [118].

Similar impairments have also been observed in models of mild to moderate injury [119], even in the absence of gross pathological lesions [55 107], which is reminiscent of the transient changes observed in humans with mild TBI [120].

Cognitive deficits were more important in subjects exposed to repeated FPI [116].

2.2.1.2.2. Motor impairment and locomotion

Motor skills are typically assessed using tasks such as the beam walk test or rotarod. Motor impairment has been observed in the early days after injury and tended to recover a few days after CCI [93] or FPI [82], although it has been observed at one month after CCI [97] [101] and up to one year after FPI [62]. Motor impairments may entail the interpretation of memory performance in tasks assessing swimming or walking patterns (reduced speed and thigmotaxis), although some authors reported a normal swimming speed in the MWM four weeks after FPI [115]. Increased torso flexion contralateral to the injury suggesting striatal damage has also been reported [54].

2.2.1.2.3. Sensory impairments

Theoretically, vision may be impaired, as studies have reported damage extending to the optic pathways [81]. However, injured animals were able to perform visual discrimination tasks using a touchscreen apparatus [98] and were able to find the platform in cued versions of the MWM [121]. Whisker dysfunction has been described after FPI. In one study [122], the authors performed a "whisker nuisance task" in which they stimulated the animal's whiskers with a wooden stick to study whisker hypersensitivity. Injured animals showed signs of pain or discomfort upon whisker stimulation. This reaction increased from one to eight weeks postinjury. Except for a CCI study where authors produced an impact in the olfactory bulb [123] and observed an impairment in olfactory function four days after injury, we did not identify studies assessing olfactory behavior using this model. One study reported decreased brainstem auditory-evoked responses [60].

2.2.1.2.4 Anxiety and depression

Depression-like behavior has been observed in animals with CCI and FPI injuries in tasks such as the forced swim test four days [116] and three weeks after injury [54], respectively, as well as in the tail-suspension test three weeks after injury [101]. No evidence of anxiety-like behavior in the elevated plus-maze [54] has been detected in animals with CCI injury, in contrast to animals with FPI injury [116].

2.2.1.3. Electrophysiology

2.2.1.3.1. Cortical activity:

Excitability

Changes in cortical neuron excitability occur in time-, layer- and region-specific patterns.

In animals subjected to FPI and CCI, in vitro and in vivo recordings showed initial hypoactivity [124], followed by an increase in activity [124], with hyperactivity observed in the first few days after injury [125] [124] that returned to normal by one week [124] before increasing again, with hyperactivity recorded after two weeks [126] [124]. Some studies have observed normal activity after eight weeks [127]. Many studies have linked late hyperactivity to a loss of inhibition [66], while initial hypoactivity has been proposed to follow the massive global depolarization of cortical cells. This latter phenomenon is called cortical spreading depressions [128] and is not specific to traumatic brain injury. It has been described in individuals with different diseases (migraine, subarachnoid hemorrhage). Cortical spreading depression induced by potassium chloride (KCl) injection in the naïve cortex have been associated with impairments in synaptic function [129], which might account for the recorded hypoactivity.

Remote electrophysiological abnormalities have been observed in a region-specific pattern. Reduced excitability of neurons in layers II and III of the prefrontal cortex has been reported seven days after FPI [69], with one study showing an increase in GAD expression in the medial prefrontal cortex (mPFC) up to one month after injury [130]. One study described a transient hyperexcitability of the contralateral cortex in the first two days after FPI [131]. In animals subjected to CCI [132], the paired-pulse ratio recorded with sensory-evoked potentials was increased at both three days and four weeks after trauma, with a return to the preinjury level in between these peaks. The authors suggested that the main mechanism responsible for this late contralateral hyperexcitability is the loss of interhemispheric inhibition.

Interhemispheric connectivity

Consistent with this observation is their finding of increased activity of the “healthy” cortex when the affected limb is stimulated. This phenomenon has been observed using different modalities (autoradiography [133], histology for immediate early genes [132], and task-based fMRI [132]). There is converging evidence that interhemispheric connectivity is decreased after CCI [134] and FPI [135]. Investigators have also found decreased connectivity between the parietal cortex and the hippocampus [135]. A graph-theory analysis of resting-state fMRI data obtained from the CCI model supports a decrease in long-range connectivity and an increase in local connectivity, which appeared to peak at one week [136]. However, researchers have not determined whether the variation in these graph-based metrics relates to changes in the excitatory/inhibitory balance in synaptic connections and underlies a potentially beneficial

plasticity mechanism. Moreover craniectomy in itself could be responsible for changes observed in BOLD (blood-oxygen-level dependent) fMRI signal [108].

EEG/LFP

An EEG analysis showed increased slow waves and decreased fast waves [60] and high frequency oscillations, which have been associated with posttraumatic epilepsy [137]. In slice preparations, slow cortical oscillations were reduced compared to the sham group for up to fifteen days after injury, suggesting an impairment in the thalamocortical networks [138].

2.2.1.3.2. Excitability and Long-term potentiation in the hippocampus:

Excitability

Slice electrophysiology showed increased excitability in mossy cells one day [139] and one week after injury [140]. Hyperexcitability was also observed in CA1[141] and CA3 [142] at one week after injury. Possible explanations include a decrease in the amplitude of Ih [139] and Ia [141] cationic currents (which are known to decrease neuronal excitability), an increase in recurrent excitation from mossy fibers [143], a decrease in GABA-A phasic inhibition [144] with relative sparing, an increase in tonic inhibition [80] [145], or a reduction in DG filtering [142]. However, recordings obtained in the first few days after injury also provide evidence for decreased excitability of DG granule cells [146] and a decrease in the firing rate in the CA1 field [147].

In vivo recordings are consistent with in vitro recordings. Hyperexcitability has been detected in the DG one week after trauma (upon paired pulse stimulation of the perforant path [64]) and up to twelve weeks after trauma [143]. Hyperexcitability has also been observed in the CA1 field in the first few hours [148] and at two days [149] after injury.

Long-term potentiation

In vitro-recordings showed decreased long-term potentiation (LTP) at the perforant path-granule cell synapse at one week [150] [151]. LTP at the CA3 to CA1 synapse was impaired for a period spanning from the first few days after injury [152] [147] [153] [154] up to eight weeks after injury [155]. However, partial recovery of LTP at the CA3-CA1 synapse has been observed at one week [156]. Possible mechanisms include alterations in the dendritic spine morphology [154], AMPA and NMDA receptor dysfunction [154] and CA1 deafferentation [156].

In vivo recordings showed decreased LTP at the CA3-CA1 synapse, as measured by the slope of the local field potential upon stimulation of the Schaffer collateral [149] [148].

EEG/LFP

One study using the FPI model showed a decrease in the theta power and in the frequency of the theta peak [105] in the hippocampal fissure one week after injury. Another study documented a decrease in broadband activity in CA1 one week after injury [157].

2.2.1.3.3. Epilepsy

Seizures have been observed in both models early after injury [158] and at later time points[159]. However, the definition of a seizure in these models is controversial [160 161].

2.2.1.3.4. Neuromodulation:

A beneficial effect of DBS applied to different targets in the FPI model has been reported, including stimulation of the raphe nuclei [162], medial septum (MS) nucleus stimulation at the theta rhythm [104], forniceal stimulation [163] and the rodent homolog of the dentate nucleus [164]. Importantly Lee et al [104] showed the benefit of restoring the theta rhythm in mesiotemporal structures. This highlights the potential benefit of restoring normal oscillatory activity in mesiotemporal structures and should guide future experimental attempts. Other neuromodulation strategies include vagus nerve stimulation [165] and transcranial stimulation. Anodal transcranial direct current stimulation over the perilesional area improved spatial memory function in the Barnes maze at one week and two weeks after FPI [166]. Two transcranial stimulation studies performed by the same team showed an increase in local field potentials (LFP) in the sensorimotor cortex and improved performance in the beam walk test in an adult model of CCI injury [167] and suggested a reduction in pathological hyperactivity in a pediatric CCI model [168].

2.2.2. Closed-skull models: weight drop, impact acceleration and blast

In weight drop models, a falling rod or a weight (dropped through a tube) falls over the unprotected skull of the animal whose head is fixed [169] (figure 1).

The impact acceleration model or “Marmarou” model [170] consists in dropping the weight on a small pedestal that has been anchored to the rodent skull to limit the occurrence of skull fractures. Importantly, in the Marmarou model, the head is not fixed, allowing acceleration forces to occur. This model is known to result in a high mortality rate due to respiratory arrest, which reflects brainstem damage and diffuse axonal injury. We mention the recent development of nonsurgical closed-head injury models, such as the Chimera model, which allow researchers to produce severe diffuse axonal injury [171]. Blast injury models have been created using explosives. While they reproduce the blast waves occurring on the battle field,

they lack reproducibility, require specific authorizations, and must be performed in a dedicated facility. Another way to model blast-induced TBI is to induce the blast wave in a tube with an animal placed either inside the tube or at the exit of the tube. This tube consists of a driving chamber (where the gas is compressed), a driven chamber (through which the blast waves propagate) and a diaphragm (which separates the two chambers) [172]. The injury severity depends on the distance from the blast wave, reflection of blast waves, and possible repetition of blast injuries. The position of the animal and the size of the tube are very important parameters that must be carefully considered, as blast physics are complex [173]. The associated hypotension and hypoxia caused by the systemic effects of the blast are likely to exacerbate central nervous system injury [174]. Some authors aim to reduce the systemic effect of the blast by protecting the torso of the animal with a Kevlar outfit [175] or with a specific apparatus [176].

2.2.2.1. Histology

Different degrees of mechanical injury, as measured by linear acceleration, movement of the head and impact force, translate into different patterns of injury [177].

2.2.2.1.1. Cortex

At the macroscopic level, weight drop models produce consistent cortical contusions similar to the damage observed with open-skull models of focal injury described above. Cortical contusions have also been observed in models of blast-induced TBI [178] but were generally not observed in impact acceleration models [179] [180]. In impact acceleration [179] models and in blast models [181] the brain appeared normal, although contusions, subarachnoid hemorrhage and intraventricular hemorrhage have been reported [179] [178].

Cell-loss

At the microscopic level, cell loss has been observed one day after injury [179] [182], and persisted in the first two weeks [183] [175] and up to one month after injury [178] [184]. “Pink shrunken neurons” and “dark contracted neurons” have been observed using hematoxylin eosin (HE) and cresyl violet staining one day after injury [169] [179], respectively, but these changes tended to disappear by 10 days after injury [179], even though they have been observed one month after blast-induced TBI [185]. Interneurons were affected with the

number of neuropeptide Y-stained interneurons in the sensory cortex decreasing one day after injury [180].

Neurodegeneration and neuroinflammation

Neurodegeneration [36] and neuroinflammation with astrogliosis [186] and microglial activation [178] have been detected in the underlying cortex.

Microscopic abnormalities are not limited to the cortex underlying the impact site, as they have also been observed in the frontal cortex [183].

2.2.2.1.2. Hippocampus

Cell-loss

Nine days after injury [183], cell loss has been reported in the bilateral DG, CA3 and CA1 as early as two hours after injury [187]. Cell loss was more important in the CA3 field [187] but has been observed in CA1 up to one month after injury [184], where pyknotic neurons were observed two weeks after injury [188]. Interneuron loss with a transient decrease in the number of neuropeptide Y-positive and calbindin-positive interneurons in CA3 has been described one day after trauma [180]. At two weeks, a decrease in neuropeptide Y-positive neurons has been observed in the DG [180].

Neurodegeneration and neuroinflammation

Evidence for astrocytosis has been reported [189] [188]. Conflicting evidence for neurodegeneration in the hippocampus has been documented. Fluoro-Jade staining in the DG has been reported by some studies in the early days [190] [191] and up to weeks after injury [188]. However, it has not been reported by other studies [67] [189]. Diffusion tensor imaging (DTI) showed pathological changes in fractional anisotropy (FA) values in the hippocampus one month after injury [185].

2.2.2.1.3. Other subcortical structures

Cell-loss

In animals with blast-induced TBI, a decrease in a specific population of neurons has been identified in the basolateral amygdala two months after injury [192].

Neurodegeneration

Diffuse lesions in the white matter are a prominent feature of models of closed-skull TBI. These lesions have been consistently reported in the corpus callosum under the site of impact. Axonal injury, characterized by diffuse axonal swelling with immunoreactivity for

APP, culminated at one day after injury [190]. Fluoro-Jade staining has been observed, although at a lower intensity than in models of FPI injury [67]. Eventually, retraction balls are formed and have been observed ten days after injury [179]. Impaired axonal transport [190], demyelination and remyelination have been detected one week and up to six weeks after trauma [193]. Multiple white matter tracts are involved, including the corpus callosum, cerebellum, brainstem, internal capsule, anterior commissure [67] and the optic nerves, which are trapped in the optic canal [179 194]. Damage has also been observed with diffusion MRI one week after injury [195 196]. White matter pathology and axonal damage are also a prominent feature of blast-induced TBI [175 197]. Changes have been observed in the optic tract [175], commissural pathways, brainstem and cerebellum.

Degeneration has also been reported in the striatum [36 67].

DTI revealed decreased FA in the thalamus at four days and one month after injury [185].

One study did not find evidence for degeneration in the amygdala using a weight drop TBI model [67].

2.2.2.2. Behavior

2.2.2.2.1. Memory

Anterograde memory

Deficits in spatial memory have been observed at one [183 198], two [199], and three [200] weeks [201] after injury. These deficits appear to persist in the long term, since they have been observed at one and three months [184 185] after injury [202]. However, in animals with blast-induced TBI, some studies did not detect deficits in the MWM at five weeks [203] and two months [204] after injury. Spatial memory impairments have also been observed in the Barnes maze in the first two weeks after injury [188]. One study did not detect a deficit in a location discrimination task in mice using a touchscreen conditioning chamber in the first few days after injury [205].

Deficits in fear memory have been observed in the passive avoidance task two days [206] and one month [207] after injury. However, similar changes were not observed in animals with a blast-induced TBI, where enhanced memory has been documented in fear conditioning paradigms [192 204]. A prolonged fear response to odors of a predator (cat urine) has been observed in injured animals compared to sham animals [204].

Deficits in object recognition have been described up to two weeks after injury [189] [208]. In contrast, other studies did not find deficits two days [209] and seven weeks after trauma [210]. According to some studies, animals who undergo repeated impact acceleration injury show greater impairments in the MWM [186] and novel object recognition task [211]. Deficits in the Barnes maze and Y-maze have been observed following repetitive TBI [186].

Behavioral impairment has been observed in rodents while the lesions were scarce [202]. Conversely, some studies did not observe memory deficits, while providing evidence for degeneration in the cortex and striatum [36].

Retrograde memory

One study reported evidence of retrograde memory deficit using a passive avoidance task [212]. This deficit was more prominent when the animal was injured shortly after the acquisition of the task, suggesting a deficit in memory consolidation. Animals benefited from a pretest shock, suggesting the coexistence of retrieval deficits. One study reported decreased performance in the MWM when animals were tested two days after blast injury [213], whereas another study did not observe deficits one day and one week after impact acceleration injury [36].

Working memory

Deficits in working memory have been observed in the swim T-maze [207] or in the MWM up to one month after injury [184]. No deficits were observed in the 8-arm radial maze at six weeks after injury [204].

2.2.2.2.2. Motor impairment and locomotion

Motor deficits have been consistently described after impact acceleration injury [177] and blast-induced TBI [197] but decreased in the first few days [177] [197] [209] [214] [175] and weeks [186] after injury, although they did not return to baseline values at one month [199]. In the MWM, no difference in swim speed has been observed one to three weeks after injury [214] [201] [200].

2.2.2.2.3. Sensory impairments

A potential visual impairment has been documented, with damage to the retina, optic nerve and optic tract [175] [197]. One study assessed visual acuity using an optokinetic apparatus and found visual deficits associated with blasts greater than 50 and 60 pounds per square inch

(psi) [197]. However, mice were able to perform a visual discrimination task after impact acceleration injury [205]. Impaired performance in whisker-evoked forepaw placement has been recorded up to six weeks after impact acceleration injury, with animals showing more aversive responses than sham animals three weeks after trauma [210]. Rats were able to perform olfactory-related memory tasks [204]. After blast-induced TBI, some animals displayed tinnitus-like auditory deficits when assessed for the startle reflex [203].

2.2.2.2.4. Anxiety and depression

Animals displayed helplessness in the forced swim test at one week and three months after injury [207]. Another study assessing these outcomes in the early days after trauma did not observe evidence of depressive-like activity using the same test and did not detect signs of anxiety-like disorders using the elevated plus-maze [36].

Regarding blast-induced TBI, animals exhibited increased anxiety in the elevated plus-maze five weeks after injury [203]. Regarding depressive-like behaviors, injured rats tended to display longer immobility in the forced-swim test when assessed three days after injury [200].

2.2.2.3. Electrophysiology

2.2.2.3.1 Cortical activity

Excitability

In the sensory cortex, hypoactivity [215] was observed in the first two weeks [126], while hyperexcitability was observed in layers II and III (supragranular layers) of the right sensory cortex (supragranular layers) eight weeks after impact acceleration injury [210]. These changes might result from a deficit in inhibition in the cortical network. Importantly, these changes in excitability have been observed in the long term (eight to ten weeks after trauma) when recording extracellular activity elicited by whisker motion [210]. Hyperexcitability is layer-specific, since inhibition appeared to be preserved in cortical layer IV (the layer receiving thalamic inputs) and was elicited only by the complex motion of the whiskers [210]. Early cortical hypoactivity in animals with a weight drop injury has been linked to the activation of parvalbumin-expressing interneurons [216]. The same study found that pharmacogenetic activation of pyramidal neurons reduced neuronal injury.

EEG/LFP

One study performing multiple site recordings after mild blast injury (50 psi) has reported decrease in sharp wave ripples (SWR) in CA1 and interestingly observed an increase in theta-gamma cross frequency coupling in the mPFC after blast-induced TBI [217].

Investigators have modified the Marmarou model to study EEG recordings after impact acceleration injury [218]. An intervention inducing or restricting sleep in animals resulted in an increase in theta activity during sleep, which was associated with better performance in the novel object recognition task [208]. Cortical spreading depression has been recorded with cortical optical intrinsic signal imaging [219].

2.2.2.3.2 Excitability and long-term potentiation in the hippocampus

Excitability

Hyperexcitability has been observed in the CA1 field [187].

Long-term potentiation

Long-term potentiation was impaired in vivo at the perforant path-granule cell synapse [206] and at the Schaffer collateral-CA1 synapse [189] [188].

2.2.2.3.3 Epilepsy

Epilepsy is not a common feature of these models.

2.2.2.3.4 Other

One study has found early changes in potentials in the rodent cerebellar cortex evoked by a mechanical tap on the forelimb following blast trauma [220].

2.2.2.3.5 Neuromodulation

A 50 Hz invasive stimulation of the motor cortex improved motor recovery and cognitive performance in the Y-maze when animals were assessed from one to two weeks after weight drop injury [221].

2.3 Provisional summary: TBI models

Although a high level of heterogeneity across studies has been observed, all rodent TBI models exhibit memory disorders and share some common features. The hippocampus is often damaged, at least at the microscopic level. Memory deficits are potentially linked to decreased LTP and increased excitability in CA1, and interneuron loss may be involved in both phenomena. Regarding the cortex, both open-skull and closed-skull models display

signs of hypoactivity (associated with cortical spreading depression waves) followed by hyperactivity, which has been linked to perturbations in complex sensory processing. However, open-skull and closed-skull models seemed to differ in the long-term (8-10 weeks) [126]. In the open-skull model, cortical firing rate returned to normal while in the closed-skull model, there was late hyperactivity affecting the upper cortical layers [126]. Importantly in the closed-skull model there was normal inhibition in layer IV, suggesting that thalamic input to the cortex was preserved [126]. Similar to the hippocampus, these changes have been linked to interneurons dysfunction. Shifts in the excitatory/inhibitory balance might be associated with plasticity mechanisms at the cortical level and might account for the observed activation of the noninjured cortex upon stimulation of the limb contralateral to injury. Epilepsy is frequently observed in open-skull injury models, while it is less frequently reported in closed-skull models. Finally, white matter injury and subcortical injury have been observed in all models, although these changes have more frequently been observed in closed-skull injury and blast models.

One study compared FPI and weight drop models. The severity of injury was similar in both models (as measured by the time to the recovery of righting reflex), but the observed deficits in the water maze test and in the radial arm maze were less substantial in the weight drop model [67].

Drawbacks of the open-skull models are related to the use of a craniotomy, which may produce brain damage itself, and may mimic the effect of a decompressive craniectomy. Also, these models fail to reproduce diffuse axonal injury and lesions to the brainstem, mostly because of the absence of acceleration/deceleration and rotational forces. These limitations hinder the translation to severe TBI in humans.

Closed-skull and blast injury models display diffuse histological damage, which prevents correlations between location of lesions and behavior. The physics of the deceleration forces and of blast waves are very complex and might limit reproducibility of these models.

Researchers have not yet determined whether the observed deficits and lesions relate to the pathophysiology observed in the clinical setting. The severity of injury is particularly difficult to determine. Although some researchers intend to produce milder injuries, the ability of these less severe injuries to represent good models of humans with mild TBI remains

unclear. Although forniceal and MS DBS have proved beneficial in a FPI model, these limitations might ultimately jeopardize the clinical translation of innovative strategies.

3. Rodent models of stroke and vascular cognitive impairment

3.1. Clinical features

Stroke is the consequence of the occlusion of a cerebral artery, due to atherosclerosis, neck vessel dissection, or cardiac embolus. Cerebral ischemia may occur in patients with other clinical conditions, such as cardiac arrest or delayed cerebral ischemia that may be complications of subarachnoid hemorrhage due to a ruptured aneurysm. The molecular mechanisms and cellular pathways activated after cerebral ischemia are beyond the scope of this review. Briefly, a sequence of events, including excitotoxicity, the release of radical oxygen species, mitochondrial dysfunction, inflammation, neuronal death, autophagy and apoptosis, occurs after stroke [222]. Importantly, the penumbra region surrounding the ischemic core, which is the focus of revascularization strategies, is likely to differ from the normal tissue in terms of neural excitability and structural and functional connectivity patterns [223].

Many studies have reported a high prevalence of cognitive disorders in stroke survivors [224] [225], and these deficits have been ranked as a key priority regarding improvements in the quality of life of patients after stroke [226]. One study [227] reported impaired scores on screening tests, such as the MMSE (Mini Mental State Examination) and MOCA (Montreal Cognitive Assessment), in up to 50% of patients at three months after stroke.

Regarding cardiac arrest survivors [228] [229], deficits also span across multiple domains, including both episodic and working memory. Many studies have linked white matter lesions and subcortical damage to cognitive impairment in patients with vascular dementia [230] [231].

Landmark neuropsychological studies have reported deficits in episodic memory after stroke or ischemia which have been linked to the selective damage of limbic structures [232]. Interestingly, memory disorders can occur when the hippocampus and mesiotemporal structures have been spared by ischemia. Cognitive deficits observed after stroke have been linked to a hypometabolism of mesiotemporal structures [233]. One study showed a correlation between cognitive scores recorded ten years after stroke and the atrophy of mesiotemporal structures measured using MRI [234]. Thus, a diaschisis [235] phenomenon can occur after stroke. This phenomenon is well established in the cerebellum and is the rationale for an ongoing phase I trial of cerebellar DBS for motor recovery after stroke [236].

Deficits after stroke span different domains (motor function, cognition, and language) and subdomains (working, episodic, visual, and verbal memory), but a recent study argued for a low dimensionality of cognitive deficits after stroke [237]. The authors of this study have identified two clusters of deficits after stroke at the highest level, namely, motor disorders/attention deficits and memory/language disorders. The frequent association of deficits across domains might be linked to the frequent involvement of subcortical structures and white matter tracts, which might result in altered functional connectivity, although the correlation between functional connectivity and anatomical connectivity is not straightforward [238].

3.2. Available models

We will differentiate between models of focal cerebral ischemia and models of global ischemia (figure 1).

Cell loss in the hippocampus is a constant feature of global ischemia models, while it is inconstantly observed in focal ischemia models. Although neurodegeneration and neuronal loss has been observed outside the affected territory in focal ischemia, extensive damage to the cortex and subcortex is a hallmark of global ischemia models. Likewise, while enduring memory deficits, especially in working memory, have been observed in global ischemia models, they are not a constant feature of focal ischemia models. The same holds true regarding hippocampal LTP which has more often been found impaired in global ischemia models than in focal ischemia models. Shifts in excitatory/inhibitory balance in the cortex and in the hippocampus have been described. Overall, these observations suggest synaptic dysfunction which might be rescued with DBS

3.2.1. Focal cerebral ischemia

Models of focal cerebral ischemia are diverse and include the intraluminal and extraluminal occlusion of arteries. Intraluminal occlusion is performed with a filament thread and the injection of thrombin [239] or a blood clot [240], which are proposed to more closely mimic the thrombotic mechanism observed in patients and are therefore useful models to study the potential benefits of thrombolytic therapies. Stereotactic or direct application of prothrombotic substances, such as endothelin-1 (ET-1) [164], has been used, along with photothrombotic models [241] involving the injection of substances (Rose Bengal and erythrosine B) that induce the release of free radicals when exposed to light. ET-1 and Rose

Bengal have even been combined in the same experiment to reproduce the penumbra and the ischemic core, respectively [242]. A major concern of scientists is the necessity of a craniotomy, which increases the complexity of surgeries and induces potential sources of bias related to a mechanical decompressive effect, in addition to the activation of inflammatory pathways. Moreover, this model does not mimic the clinical condition of patients with acute ischemic stroke, in whom a craniectomy is seldom necessary, although it is useful in a subgroup of patients.

A solution to avoid craniectomy is the filament technique [243], where a coated suture is inserted in the carotid artery and ascends in the cranium up to the termination of the internal carotid artery, where it occludes the initial segment of the middle cerebral artery. However, the size of the infarction is not always reproducible and inconsistent involvement of subcortical structures has been reported across studies, due to the involvement of perforating arteries [244]. As an alternative, infarction of the sensorimotor cortex has been produced by occluding the distal segment of the middle cerebral artery, a technique that was initially developed in one study [245], which has the major disadvantage of requiring a craniotomy but produces very reproducible ischemia that spares the subcortical structures. These focal vessel occlusions have often been paired with permanent or intermittent occlusion of common carotid arteries to avoid reperfusion of ischemic territories by collateral vessels. Rodent models of subarachnoid hemorrhage have also been developed, which are not discussed here but have been reviewed elsewhere [246].

3.2.1.1. Histology

3.2.1.1.1. Cortex

Both proximal middle cerebral artery occlusion (MCAO) and distal MCAO injure the sensorimotor cortex, and damage has been reported to extend to the posterior parietal cortex and auditory cortex [247]. Damage to the piriform cortex and entorhinal cortex [248], which does not belong to the territory of the middle cerebral artery, has been noted in models of intraluminal middle cerebral artery occlusion.

Ischemic lesions are associated with edema, which must be considered when assessing the volume of the ischemic lesion [249].

Damage to the prefrontal cortex has been most reliably modeled using photothrombotic [250] or ET-1 injection models [251] [252].

Cell-loss

Models of transient MCAO produce selective neuronal loss, which has been reported to appear a few days after reperfusion in the cortex and overlapped with areas of microglial activation [253] without necrosis or persistent abnormalities on diffusion MRI.

3.2.1.1.2. Hippocampus and subcortical structures

Depending on the method (proximal MCAO versus distal MCAO, filament occlusion versus direct surgical approach), the extent of the infarction varies.

Ischemic lesions in the striatum

While distal MCAO injury is typically limited to the cortex, reproducible involvement of the striatum has been reported in the proximal MCAO model [254] [255] (as well as in some reports of distal MCAO [256] [249]), where selective neuronal loss has been observed [257].

Ischemic lesions in subcortical structures outside the territory of the middle cerebral artery

Ischemia in subcortical structures outside the territory of the middle cerebral artery, including the hippocampus, has been observed in filament models of proximal MCAO [255], possibly in relation to the involvement of deep perforating arteries [244]. The ischemic territory also included the amygdala [255] [244], the hypothalamus [244], and, more rarely, the thalamus [244] [255]. Importantly, in many studies of distal MCAO investigators performed an additional occlusion of one [249] [247] or both [258] [259] [245] [260] [261] [262] [263] carotid arteries. In one study where the authors definitively occluded the carotid artery ipsilateral to the occluded MCAO, ischemic lesions were observed in CA1 [259].

3.2.1.1.3. Lesions outside the ischemic territory

Interestingly, damage has been reported in zones distant from the site of the infarction. Studies have also reported a decrease in the size of the thalamus [250] [264] after middle cerebral artery (MCA) stroke.

Cell-loss

In a proximal MCAO model, a decrease in the number of cholinergic projections (assessed with acetylcholinesterase immunochemistry) to the frontal cortex was observed, without evidence of damage to the nucleus basalis of Meynert [265].

Neurodegeneration

One study [266] using a proximal MCAO model sparing the thalamus and hippocampus has reported the accumulation of manganese (observed with manganese-enhanced MRI (MEMRI)) in the thalamus after injecting the substance in the entorhinal cortex. This finding is consistent with other studies showing silver staining in thalamic preparations [267]. Secondary neurodegeneration after MCA stroke in humans and in animals has been reviewed in a previous study [268]. Interestingly, Alzheimer's-like A-beta deposition in the sensory thalamus has been identified after MCAO occlusion in rodents, which might result from axonal injury [269].

Degeneration in the corpus callosum and contralateral cortex have also been documented [267].

3.2.1.2. Behavior

3.2.1.2.1. Memory

Anterograde memory

An animal model of surgical proximal MCAO exhibited decreased performance in learning MWM tasks at one [270] and two months [271] after injury. However, some authors reported negative results using the same model [272]. Impaired fear memory in the passive avoidance task has been reported at one week after injury [273]. Studies of the distal MCAO model are scarce, but decreased performance in the Barnes maze and in the social transmission of food preference task has been observed at two weeks after injury [258]. Deficits in fear memory have been documented in the passive avoidance task at one week [259] and seven weeks after injury [271]. However, two studies (one with transient ligation of the carotid arteries [260] and one without [274]) did not observe any impairment in the MWM at one and two weeks after injury, as well as in the passive avoidance task [274].

Retrograde memory

Deficits in tasks learned before stroke have been observed in the MWM at eight weeks after injury [275] and in the passive avoidance task at one [276] and three [275] weeks after injury.

Working memory

After surgical proximal MCAO, rats exhibited poor performance in the radial arm maze task at one and two months after injury [277]. However, another study using the same model did not observe deficits in the Y-maze three days after stroke [273]. Using the distal MCAO model,

one study [247] did not observe deficits in spontaneous alternation in the T maze at three weeks after injury.

Cognitive flexibility

Deficits in attentional set shifting, an odor-texture based task [251], or in the plus-maze [252] have been observed in rodents at ten and eight days, respectively, after the establishment of a stroke in the bilateral prefrontal cortex (induced by ET-1 injection). However, one study using a photothrombotic stroke model in which the authors induced a stroke in the prefrontal cortex showed no deficits in reversal learning at one month after stroke with a touchscreen-based visual discrimination task [278].

Memory impairments without lesions in the hippocampus

Interestingly, one proximal MCAO [277] and two distal MCAO [258] [259] studies reported memory deficits without damage to the hippocampus.

Another study has described impairments in spatial memory after prefrontal stroke, which were associated with a decrease in volume of the mediodorsal thalamus [250].

3.2.1.2.2. Sensorimotor impairment

In permanent [279] [273] [260] and transient proximal MCAO models [280], motor deficits have been observed in the contralateral hemisphere. A rapid recovery with a return to sham levels occurred by four weeks [270] [266], allowing animals to perform cognitive tasks. However, long-lasting deficits in the inclined plane test [281] and in tests assessing forepaw dexterity and sensorimotor integration, such as the staircase test, the limb placing test and adhesive removal test [264] have been observed two to three months after injury.

In the distal MCAO model, deficits were milder [282] and animals recovered more quickly, with near sham performance observed at one week [260]. However, deficits have been observed at three weeks using appropriate tasks, in particular the adhesive removal task [283] [274] and tasks assessing forepaw asymmetry (cylinder test), forepaw inhibition (swimming tasks), tongue extension, reaching and fine motor tasks [284]. These findings have specifically been observed in aged rats [263].

3.2.1.2.3. Sensory impairment

We are not aware of any study assessing visual function in models of focal stroke. Animals performed normally in the cued version of the MWM [270]. However one study reported the

impaired performance of mice in a touchscreen-based visual discrimination task when the level of similarity between the two images was high [285].

One study used optical intrinsic signal imaging in a MCAO model to study the changes in cortical hemodynamics elicited by whisker stimulation. An increase in latency was observed in stroke rats compared to controls [286].

After distal MCAO, rats were able to perform a social transmission of food preference task, although model animals displayed worse performance when compared to animals of the sham group [258].

3.2.1.2.4. Neuropsychiatry

Animals showed signs of motor hyperactivity following right MCAO but not after left MCAO [287] [288].

Anxiety-like behavior has been observed nine weeks after injury in animal models of left MCAO [288]. Depressive-like phenotypes were observed in animal models of left MCAO (in ovariectomized rats) [289] and animal models of right MCAO at three weeks after injury [290]. Right MCAO combined with social stress has been associated with depressive-like behaviors for up to two weeks after injury (spatial restraint in a 50 mL tube [291]). These findings have been reviewed in a previous study [292].

Anxiety-like and depressive-like behaviors were also observed at one week and two weeks, respectively, in a mouse model in which ET-1 was injected in the left mPFC [293]. No anxiety-like behavior (assessed with the elevated plus maze) was reported at one week and one month after injury in a photothrombotic model of bilateral mPFC stroke [250].

3.2.1.3. Electrophysiology

3.2.1.3.1. Cortical activity

Excitability

In vitro recordings in the perilesional cortex have produced conflicting data. One study [294] reported hyperexcitability and increased long-term potentiation in the peri-infarct cortex one week after a photothrombotic stroke, while another study by the same group [295] showed a decrease in field potentials at one week and one month after transient MCAO. This hypoexcitability might be related to increased tonic inhibition due to the decreased reuptake of GABA by astrocytes [223], while the hyperexcitability observed in the photothrombotic model might be related to decreased inhibition, as evidenced by decreased

paired-pulse inhibition at one week after injury [296]. Decreased paired-pulse inhibition was also observed in the hemisphere contralateral to a photothrombotic stroke [297].

Interhemispheric connectivity

This increased excitability might be related to a decrease in inhibitory output from the ischemic cortex to the contralateral cortex. fMRI [298] [299], EEG [298] and optical intrinsic signal imaging [300] studies have provided evidence of decreased interhemispheric connectivity after stroke. In one study [298] normalization of interhemispheric connectivity was associated with motor recovery. In another study which evaluated intracerebral injection of neural stem cells, the decrease in interhemispheric connectivity was more important in the control group [299]. However another study performed in rats six months after MCAO did not find changes in interhemispheric connectivity compared to controls [301]. In this study, rats with stroke displayed increased connectivity in the ventromedial thalamus compared to control rats.

EEG/LFP

Using EEG, many studies reviewed in a previous report [302] have observed a decrease in global power, decreases in alpha and beta power and an increase in delta activity [303] [304], resulting in a decreased alpha-to-delta ratio, consistent with findings in patients with stroke [305]. Interestingly, in cat lesion models, polymorphic delta activity is associated with damage to the white matter and the reticular formation (particularly the mesencephalic reticular formation) [306]. In the contralateral hemisphere, a slight increase in delta activity along with a decrease in alpha activity have been observed. An initial decrease followed by an increase in beta activity has been documented [307]. Reports have also described increased non-REM and decreased REM sleep using EEG [308].

Regarding the recordings of DC potentials, peri-infarct depolarization has also been observed [309].

3.2.1.3.2. Long-Term Potentiation in the hippocampus

One study observed impaired LTP in CA1 after transient MCAO [248]. The authors argued that the LTP impairment in both hippocampi (ipsilateral and contralateral) might be due to increased inhibition. Another study found a similar impairment in LTP in the ipsilateral hippocampus, but not in the contralateral hippocampus [310]. Interestingly, none of these studies included additional ligation of common carotid arteries, meaning that transient global ischemia does not account for the observed disturbances. However, another study did

not detect an LTP impairment after MCAO [277]. Recordings performed in animals immediately after distal MCAO showed a decrease in theta-gamma cross-frequency coupling in the hippocampus [311].

3.2.1.3.3. Epilepsy

Two studies [312] [313] using a photothrombotic model of focal stroke observed convulsive seizures. Using the same model, one study [241] correlated seizures (with motor arrest) with an increased excitability of thalamocortical cells.

Two studies [304] [314], which have been reviewed in a previous article [315], observed non convulsive seizures in an MCAO model. Spike discharges and sharp-wave complexes have been recorded after MCAO [307]. These features resemble the periodic lateralized epileptiform discharges (PLEDs) that have been recorded in patients with stroke [316].

3.2.1.3.4. Other

Hypometabolism in the striatum and decreased connectivity between the striatum and hippocampus have been observed in ^{18}F-fluorodeoxyglucose PET studies in rats twelve hours after a transient filament MCAO [317]. In vitro electrophysiology showed increased long term potentiation in striatal neurons during the first week after MCAO [318].

3.2.1.3.5. Neuromodulation

We are not aware of any neuromodulation study aiming to improve cognitive function in focal stroke models. However, one of the aforementioned studies showed the feasibility of a closed-loop optogenetic strategy to silence thalamic neurons and reduce the number of seizures in a photothrombotic stroke model [241].

Two groups described the benefit of stimulating either the motor cortex at 50 Hz [319] or the rodent homolog of the human dentate nucleus to promote motor recovery in an animal model of ET-1-induced stroke in the sensorimotor cortex [164] and a distal middle cerebral artery occlusion model [320]. Similar results have been obtained with optogenetic neuronal stimulation of the same target in a filament model of MCAO [321].

3.2.2. Global ischemia

Different models of global ischemia reproduce very different clinical situations, depending on the nature of ischemia (two vessel occlusion (2VO), also known as bilateral carotid artery occlusion (BCAO), or four vessel occlusion (4VO)), the duration of ischemia, and associated factors (hypoxia, hypotension, and hypoglycemia). Importantly, the same models produce very different lesions in different species. Due to an incomplete circle of Willis, BCAO causes profound forebrain ischemia in mice and gerbils. This model mimics the condition observed after cardiac arrest, while the establishment of the same model in rats more closely resembles a chronic cerebral hypoperfusion model, because the circle of Willis allows for compensation [322]. Some models, such as bilateral carotid artery stenosis (BCAS), are more similar to humans with vascular dementia (chronic cerebral hypoperfusion). Other models attempt to specifically reproduce cardiac arrest (and not only cerebral hypoperfusion) in rats [323].

We can thus differentiate between cardiac arrest-like models that provoke complete forebrain ischemia (cardiac arrest, 4VO [324], and 2VO in gerbils, and 2VO combined with hypotension) and vascular dementia-like models that resemble chronic cerebral hypoperfusion, such as BCAO and BCAS [322]. In BCAO models, compensatory mechanisms allow blood flow to return to normal after an acute decrease in perfusion [322]. Progressive BCAS is produced by the progressive introduction of coils in the carotid lumen or by the application of progressive pressure on the carotid arteries through extraluminal cuffs. Some teams [325] prefer to sequentially occlude the two carotids over a one week period, because simultaneous bilateral carotid occlusion is associated with a very high mortality rate. Specific models of the consequences of early life ischemia/hypoxia have also been developed [326] such as the Rice-Vanucci model [327], which combines ligation of the ipsilateral carotid artery with hypoxia in rats at postnatal day 7.

However, despite the large number of models and clinical situations, some common behavioral, histological, and electrophysiological findings can be described.

3.2.2.1. Histology

3.2.2.1.1. Cortex

Damage has been observed in the cortex [328] one week after a 6-minute ischemia in the 2VO model.

Cell-loss

Delayed neuronal cell death was predominantly observed at the border between the territories of the anterior and middle cerebral arteries, but parasagittal lesions suggestive of a venous pattern of injury were also observed [328]. Studies have reported modifications of the dendritic architecture in the prefrontal cortex after a 15-minute 4VO [329]. Cortical layers III and V were the most frequently affected layers [328 329], with possible additional damage in layers IV [328] and VI [324]. In the Rice-Vanucci model of perinatal infarction, cortical damage displayed a columnar distribution, namely, it occurred in columns perpendicular to the pial surface that comprised all cortical layers [327].

3.2.2.1.2. Hippocampus and other subcortical structures

The hippocampus is known to be particularly vulnerable to ischemic injury.

Cell-loss

Neuronal loss has been observed after a few minutes of ischemia in the CA1 region [330] and appeared to predominate in the dorsal part of the hippocampus. However, cell death has not been observed until two to three days after injury [331 332], prompting questions about the mechanisms involved in cell death (necrosis versus apoptosis) [333]. This pattern of delayed cell death has also been observed in humans [334]. Neuronal loss has also been observed in other regions, such as the transition between CA3 [335] and the DG [336], with damage to interneurons (neuropeptide Y-positive and somatostatin-positive interneurons) [337 338] and mossy cells [335]. In models of BCAS, damage has inconsistently been reported in the hippocampus [339 340].

The striatum [341 342] and the cerebellum [343] have been reported to be very sensitive to ischemia . Lesions in the septal nucleus, the reticular thalamus, the substantia nigra pars reticularis and amygdala have also been observed [344]. Time and other factors, such as hypothermia and anesthesia, have been shown to affect the extent of neuronal loss [336 341 342].

Neurodegeneration

White matter lesions, which are frequently observed in patients with vascular dementia and cardiac arrest, have been shown to occur after transient forebrain ischemia in models of neonatal anoxo-ischemia [345] and in chronic hypoperfusion models, such as BCAO [342] or BCAS [322 339 340].

Retinal ischemia and optic nerve damage have been reported in models of global ischemia [346] [347] [348] [349], which may complicate behavioral assessments. Brain damage appeared to be more severe after common carotid artery ligation compared to internal carotid artery ligation [350].

3.2.2.2. Behavior

3.2.2.2.1. Memory

Anterograde memory

Deficits in anterograde memory have been observed using the MWM at two [351], three [352] and seven [353] weeks after injury. However, studies have not observed a deficit in the MWM after BCAS [339] [354], suggesting that the main deficits might occur in working memory (see below). In cardiac arrest-like models, deficits have been observed in the MWM at three [355] and six [356] weeks after injury, as well as four months after injury when the difficulty of the task was increased [357]. Deficits have also been observed in the Barnes maze at one week after injury [323], in object recognition tasks at one [358], two [325], and three months [325] after injury, and in fear memory at one [323] [359] and four weeks after injury [359].

Interestingly, some studies [360] [355] reported a poor correlation between the performance in the MWM and the number of neurons in CA1, while others reported the opposite conclusion [361]. Rats that underwent hippocampectomy immediately after ischemia performed better in a delayed non matching to sample task compared to rats which did not underwent hippocampectomy [358].

Retrograde memory

Deficits in retrograde memory have been observed in chronic hypoperfusion models using the MWM at seven weeks after injury [353].

Working memory

In cardiac arrest-like models, deficits in spontaneous alternation in the T-maze have been observed in the first week after injury [362]. Deficits have also been observed in the hole-board test at one and two weeks after injury [363], as well as in the radial maze at eight to fifteen weeks after injury [357].

In chronic hypoperfusion models, injured rats displayed worse working memory performance in the eight arm radial maze at four weeks [340] [354] to sixteen months after injury [364], and in the Y-maze at four [339] [325], eight [325] and twelve weeks [325] after injury. Interestingly,

in these models, working memory deficits tended to appear or to worsen over time [339 325 360 364].

3.2.2.2.2. Motor impairment

Models of global ischemia produced a motor impairment that may include decreased forepaw activity [341], gait deficits [325] and severe akinesia [341]. Locomotor activity was typically increased [341 359], but some studies reported that locomotor activity [356 340] and swimming speed in the MWM were identical to those of controls [355 339].

3.2.2.2.3. Sensory impairment

Damage to the retina or the optic tract reviewed in the previous section raises concern regarding a potential visual impairment. The pupillary light reflex has been shown to be altered after 2VO in half of the injured animals [349 365], and to influence the performance of animals in the MWM and radial arm maze [365]. However, in other studies, ischemic rats were able to perform normally in the cued version of the MWM [354 357]. These discrepancies have been reviewed in a previous report [322].

The response to vibrissae stimulation was studied by some authors [325], but they did not report the results of this evaluation.

We are not aware of studies assessing olfactory or auditory functions in these models.

3.2.2.2.4 Neuropsychiatry

An increase in locomotor activity has been postulated to be related to increased anxiety. However, the few studies [366 367] assessing rodents using the elevated plus maze support the hypothesis that anxiety is decreased after global ischemia.

We identified a few studies assessing depressive-like behavior in rodents. Two studies that assessed depressive-like behavior one month and three days after permanent [368] or temporary [366] BCAO in mice, respectively, observed increased immobility of ischemic animals in the forced swim test or tail suspension test. However, another study [340] performed BCAS in mice and did not observe a difference in the forced swim test at one week after injury.

3.2.2.3. Electrophysiology

3.2.2.3.1. Cortical activity

EEG/LFP

During the period of complete forebrain ischemia, electrical activity recorded with EEG has been shown to completely disappear [369], while an initial 80% decrease in the amplitude of the signal has been observed in the BCAO model [370].

One consistent finding from various models of forebrain ischemia is a decrease in theta activity recorded with EEG [371 370 372]. Increases in beta and delta activity have also been documented [370].

Neonatal hypoxia ischemia has been shown to alter network synchrony between the prefrontal cortex and the hippocampus in the absence of overt lesions, as assessed using histology and MRI [373]. In that study, the authors showed a reduction in gamma oscillations nested in slow oscillations in the prefrontal cortex. In adult rats submitted to asphyxial cardiac arrest while in infancy, there was evidence of increased latency in cortical activations upon sensory stimulation (whisker deflection [374] or auditory stimulus [375]).

3.2.2.3.2. Excitability and Long-Term Potentiation in the hippocampus

Excitability

While studies using 2VO models in gerbils have shown increased activity in CA1 neurons in vivo at seven hours after a five-minute ischemia [376], two in vivo studies using the 4VO model in rats reported decreased activity in CA1 [372 377] and in the DG [372] at four to seven days after a seven to fifteen minute episode of ischemia.

Evidence for increased CA3 excitability has been obtained using in vitro recordings performed two to four months after a twenty-minute 4VO ischemia in rats [378].

Long-term potentiation

In hippocampal slice preparations, the induction of hypoxia and exposure to a low glucose concentration has been shown to result in a special type of long-term potentiation called anoxic (or ischemic) long-term potentiation associated with the activation of NMDA receptors by ischemia [379 380]. This result has been confirmed in vivo [381] in the first 24 hours after ischemia, although the evidence suggests the coexistence of a depression of synaptic responses in other CA1 cells in the same animals [382]. In a rodent model of cardiac arrest [383], ischemic LTP was shown to preclude the appearance of physiological LTP in slice preparations. Disturbances in LTP were observed in vitro at eight weeks after 4VO [356] along with an increase in paired-pulse facilitation one week after injury, suggesting disturbances in presynaptic mechanisms [323]. Indeed, in vivo studies also reported impaired LTP in rats two

weeks after 4VO [363] and two to three weeks after 2VO [384] [385]. Low frequency (0.5 Hz) stimulation of Schaffer collaterals has been shown to reverse [383] this ischemic LTP and to help restore physiological LTP. Researchers are still debating whether ischemic LTP is beneficial in the early phases of ischemia [383]. Studies have shown the effects of thrombin on the induction of ischemic LTP [386]. Other studies have described decreased LTP in the DG after transient BCAO in irradiated rats [387].

EEG/LFP

Regarding oscillatory activity, hippocampal theta activity rapidly decreased after 4VO [371] [372]. Hippocampal LFP recordings in a 2VO vascular dementia model showed a decrease in theta-gamma cross-frequency coupling three weeks after 2VO that was associated with decreased LTP and information transfer between CA3 and CA1, the latter of which was assessed by computing general partial directed coherence [385].

3.2.2.3.3. Epilepsy

Damage to the substantia nigra has been linked to poststroke epilepsy [344]. Researchers have proposed that the behavioral deficits displayed by the animals might result from epileptic activity in the hippocampus. Results showing an improvement in the behavior of rats hippocampectomized before or one hour after ischemia support this hypothesis [358].

3.2.2.3.4. Neuromodulation

A single one-hour session of 130 Hz DBS of the entorhinal cortex performed two weeks after 4VO (including 15 minute BCAO) improved rats' performance in the MWM at 6 weeks after injury [356]. This study also showed that DBS was associated with an increase in synaptophysin expression, suggesting that DBS might rescue synaptic dysfunction in this model with extensive damage.

3.3. Provisional summary: ischemia models

Unlike TBI, not all ischemia models produce memory disorders. The main reason for this discrepancy is that these models obviously produce very different patterns of injury and result in different behavioral outcomes that correspond to different clinical situations (stroke, vascular dementia, and cardiac arrest).

While the hippocampus is often not involved in the ischemic territory in models of focal strokes, it is involved in models of global ischemia. Indeed, neuronal cell death has been observed in the hippocampus only a few minutes after global ischemia. However, hippocampal ischemia does not appear to be necessary to observe impaired LTP. This finding might account for the memory deficits observed in the distal MCAO model, although the fact that this model often includes additional BCAO is an important confounding factor. The hypothesis of a hippocampal diaschisis remains to be confirmed, but the reviewed studies acknowledge the fact that structures outside the ischemic territory, particularly the thalamus belonging to the classical Papez circuit, may be affected after stroke.

Similar to brain trauma, a shift in the excitatory/inhibitory balance appears to occur in the hippocampus and in the cortex, suggesting that some common pattern of brain reorganization, at least in the cortex, might occur after ischemic or traumatic brain injury.

Focal ischemia models are appealing since they tend to produce reproducible lesions, with low mortality rates. One limitation is the difficulty of the surgical technique, which involves the microsurgical dissection of very small vessels. Another limitation is the collateral circulation, which is very efficient and variable in rodents, and therefore limits the reproducibility of lesions.

Global ischemia, either cardiac arrest or hypoperfusion models, consistently produces memory disorders. However, similar to the diffuse TBI models, the widespread distribution of damage hinders correlations between location of lesions and behavior. Additionally, the retinal damage that is frequently observed in these models limits the interpretation of cognitive tests.

Deficits in theta-gamma phase amplitude coupling have been observed in focal and global ischemia models, but focal stroke models appear to be more appropriate to investigate neuromodulatory strategies, as the structures to stimulate (for instance, the fornix) are intact.

4. Discussion

TBI and ischemia models produce impairments in memory tasks and structural and functional alterations, as evidenced by histology and electrophysiology. These models could enable researchers to study the mechanisms of action of DBS at the network level [388] [30]. Changes in behavior of rodents probably result from complex interactions between brain regions, including the cortex and hippocampus, whose activity can be studied with electrophysiological recordings and functional imaging (histology of immediate early genes, fMRI, and PET).

4.1. Hippocampal dysfunction

Cell loss in the hippocampus is frequently encountered across all models. While a clear and preferential involvement of the CA1 field has been documented in ischemia, cell loss most frequently occurs in CA3 and the DG in response to trauma but can also affect CA1.
Damage, particularly in the DG, has been linked to hyperexcitability in the hippocampus. Our review of electrophysiological findings and another recent review focusing on stroke [389] show that **LTP in the hippocampus is disrupted in most animal models of TBI and stroke**.

4.2. Beyond the hippocampus

While hippocampal damage and dysfunction are the areas of focus of most investigations, this review emphasizes that the damage extends beyond the hippocampus, including the white matter and subcortical structures such as the thalamus. Moreover, animals may display impairments in spatial memory tasks even when no damage is observed in the hippocampus. Reports have even documented improved behavioral performance of hippocampectomized ischemic animals [358]. There is also evidence that pharmacological interventions aiming at reducing neuronal activity in CA3 are associated with improved performance of aged rats in cognitive tasks [390].

4.3. Shift in the excitatory and inhibitory balance

In models of stroke or TBI, many studies have initially observed hypoactivity in the injured cortex followed by late hyperactivity. Hyperactivity has also been observed in the contralateral cortex and hippocampus in the days following injury. This change has been

observed in models of TBI and stroke and has been linked to a decrease in inhibition by interneurons, which appears to be a common feature of the injured brain across models, since it has also been observed in animal models of experimental autoimmune encephalitis [391]. We also reviewed data showing reorganization of the sensory map assessed with functional imaging after stroke or TBI, which suggests that these changes in excitability might be compensatory mechanisms.

4.4. Possible role of long-range synchrony and relation to structural lesions

Although long-range synchrony has only been assessed by few studies, disturbed long-range synchronies, a decrease in theta-gamma phase amplitude coupling, and modifications in functional connectivity metrics have been reported. These findings appear to be consistent with clinical data showing that abnormal functional connectivity may account for the neurological impairments observed in patients with stroke [237] and TBI [51], while theta-gamma phase amplitude coupling has been shown to correlate with cognitive performance in patients with epilepsy [392] [393] and Alzheimer's disease [393]. There is also evidence from fMRI studies in rats that hippocampal LTP induction through stimulation of the perforant path was associated with increased interhemispheric functional connectivity [394]. Recently, investigators [395] proposed a mathematical model to study the alterations in spike train transmission due to focal axonal swelling, a histological lesion that is frequently observed in patients with TBI (as well as in patients with neurodegenerative diseases). The lower gamma frequency band (approximately 40 Hz, involved in memory retrieval) was robust to alterations in spike train transmission, while the higher gamma frequency band was susceptible to injury.

4.5 Restoring theta-gamma phase amplitude coupling

An increase in theta-gamma phase amplitude coupling has been associated with an increase in long-term potentiation in the hippocampus [396] [397]. Conversely, a decrease in theta-gamma phase amplitude coupling has been associated with a decrease in long-term potentiation at the CA3-CA1 synapse in a 2VO model [385], as reviewed in the global ischemia section.

The restoration of theta-gamma phase-amplitude coupling in these models might be associated with an increase in LTP. This hypothesis is consistent with the results of

experiments using rodent models which showed the ability of forniceal [398] and entorhinal cortex [29 356] DBS to restore synaptic activity.

Recently, strategies to reestablish theta-gamma phase amplitude coupling in the hippocampus using closed-loop stimulation of the fornix were proposed [388]. The next step is to design DBS experiments that aim to correct cross-frequency coupling deficits in these animal models. If improvements in behavioral tasks and electrophysiological parameters (such as LTP) were observed, these findings would confirm the role of long-range synchrony in the pathogenesis of cognitive disorders and validate the hypothesis that they should be the targets of neuromodulatory strategies in humans. The safety of these interventions must also be assessed. Researchers have not determined whether restoring theta-gamma PAC promotes the development of epilepsy. A study in a rat model of epilepsy showed that the amplitude of prefrontal gamma activity was modulated by the phase of the hippocampal theta wave during the preictal period [399]. Recordings in the seizure onset zone of patients with epilepsy showed that the amplitude of high-frequency oscillations is modulated by the phase of alpha waves [400].

Animal models will also be useful to obtain an understanding of the mechanisms linking theta-gamma phase amplitude coupling to cognition. The effects of correcting theta-gamma phase amplitude coupling on the excitatory/inhibitory balance and particularly on the function of GABAergic interneurons, which are known to be implicated in long range synchrony, should be studied.

4.6. Which structure(s) to target?

The disorders in long-range synchrony observed in these models are consistent with the diaschisis hypothesis described more than a century ago by von Monakow [401 235], which has fundamental and practical implications for functional neurosurgery. A strategy could be to try to restore normal oscillatory activity in a circuit by stimulating structures that have been spared from damage. This approach is the rationale for an ongoing DBS trial [236] in which investigators are stimulating the cerebellum (in an open-loop stimulation paradigm) to improve motor function after stroke. For memory disorders, steering strategies could be targeted to the fornix as previously suggested [30,388], or to the thalamus, a structure implicated in long-range synchrony and part of the circuit of Papez, as a continuation of the

fornix. Furthermore thalamocortical circuits have been shown to modulate long-term potentiation in the cortex [402]. Moreover, midline structures in the thalamus have been involved in hippocampal-prefrontal coupling [403].

In this regard, the distal middle cerebral artery occlusion appears as the most interesting model, since the hippocampus, thalamus, fornix, and entorhinal and prefrontal cortices are spared from ischemia. However our review shows that DBS has demonstrated clinical benefit in models with extensive damage to subcortical structures (FPI, Global Ischemia).

4.7. Other challenges

The time at which stimulation must be initiated is unknown. Many studies have shown that the neuronal excitability in the cortex and in the hippocampus is either increased or decreased, depending on the time that has elapsed since the injury. Researchers have not determined whether an optimal window exists to enhance endogenous plasticity mechanisms or the effect of rehabilitation strategies. However, from the perspective of clinical translation, a more rational strategy is probably to assess DBS in a chronic setting, since the implantation of DBS leads is unlikely in patients at the acute or subacute phase after a stroke or TBI.

Another challenge related to the preclinical assessment of DBS is the choice of the most appropriate cognitive task or set of tasks. Most studies performed spatial memory tasks assessing working, retrograde and anterograde memory. However, multiple possible confounding factors must be considered when analyzing these results. Indeed, the lesions produced in the reviewed models have been shown to affect the motor and sensory (vision and whisker function) performance of animals, which showed signs of depression and anxiety in some studies. In rodent studies, paradigms are also available for assessing fear memory and olfactory memory. However, simple memory tasks do not recapitulate the full complexity of human cognition. Touchscreen-based conditioning chambers allow the realization of more complex tests (such as paired associate learning and reversal learning), which are more similar to the neuropsychological evaluations performed in patients. Finally, regarding steering strategies, the design of the cognitive tasks should allow researchers to differentiate between the encoding and retrieval of information. Improvements in the assessments of rodents' cognitive abilities are of the utmost importance, since they are likely

to facilitate clinical translation, but they might also prevent the scientific community from discarding new stimulation strategies that might be effective for improving very specific aspects of cognition.

4.8. Limitations of this review

Our review has some limitations. We only focused on traumatic brain injury and cerebral ischemia and did not review studies using other rodent models of memory disorders (such as neurodegenerative diseases, epilepsy, ovariectomy, or alcohol intoxication). We also did not review studies using other species (dogs, swine, or nonhuman primates), which might more closely mimic the pathological and behavioral outcomes observed in humans. Indeed, the rodent cortex is lissencephalic and the proportion of white matter is smaller than that in humans. These parameters are very important in traumatic brain injury because they may influence the biomechanics of cerebral injury. White matter lesions are a major pathological hallmark of vascular cognitive impairment and traumatic brain injury. We did not provide a detailed review of the performance of rodents in behavioral tasks. The interpretation of behavioral tasks is challenging and subject to many biases. Moreover, none of the tasks reviewed here closely mimic human episodic memory, which is one of the targets of neuromodulatory strategies in humans.

Furthermore, we did not investigate sleep, which is known to be disturbed after stroke and TBI in humans, and in patients with neurodegenerative diseases. Sleep is associated with increased synchrony in thalamocortical circuits, and oscillatory activity in the cortex and hippocampus during sleep has been shown to modulate memory consolidation [404] [405]. In this regard, an analysis of sleep patterns in these preclinical models [308] and an analysis of potential effects of DBS on sleep would be highly relevant.

5. Conclusions

Our review highlights the potential of rodent TBI and stroke models to assess the mechanisms of action and the efficacy of new methods of DBS some of which were already translated to the the clinic in patients with AD.

One major limitation of these models is that they are very heterogeneous in terms of the distribution and severity of injury. This inherent weakness is also one of their main strengths

and justifications, as they have the potential to model the entire scope of human pathology, which is also characterized by a very high level of interindividual variability. We advocate for a translational approach in the selection of the proper experimental model to assess the efficacy of DBS. In particular, the insights obtained from lesion-symptom mapping, fMRI and electrophysiological experiments investigating specific behaviors or symptoms should guide researchers to choose the model and task that most closely resemble assessments of human cognition.

1. Hamani, C. *et al.* Memory enhancement induced by hypothalamic/fornix deep brain stimulation. *Ann. Neurol.* **63**, 119–123 (2008).
2. Lozano, A. M. *et al.* A Phase II Study of Fornix Deep Brain Stimulation in Mild Alzheimer's Disease. *JAD* **54**, 777–787 (2016).
3. Kuhn, J. *et al.* Deep brain stimulation of the nucleus basalis of Meynert in Alzheimer's dementia. *Mol Psychiatry* **20**, 353–360 (2015).
4. Gratwicke, J. *et al.* Bilateral Deep Brain Stimulation of the Nucleus Basalis of Meynert for Parkinson Disease Dementia: A Randomized Clinical Trial. *JAMA Neurol* **75**, 169–178 (2018).
5. Gratwicke, J. *et al.* Bilateral nucleus basalis of Meynert deep brain stimulation for dementia with Lewy bodies: A randomised clinical trial. *Brain Stimul* **13**, 1031–1039 (2020).
6. Maltête, D. *et al.* Nucleus Basalis of Meynert Stimulation for Lewy Body Dementia: A Phase I Randomized Clinical Trial. *Neurology* **96**, e684–e697 (2021).
7. Suthana, N. *et al.* Memory enhancement and deep-brain stimulation of the entorhinal area. *N Engl J Med* **366**, 502–510 (2012).
8. Jacobs, J. *et al.* Direct Electrical Stimulation of the Human Entorhinal Region and Hippocampus Impairs Memory. *Neuron* **92**, 983–990 (2016).
9. Titiz, A. S. *et al.* Theta-burst microstimulation in the human entorhinal area improves memory specificity. *eLife* **6**, e29515 (2017).
10. Mankin, E. A. *et al.* Stimulation of the right entorhinal white matter enhances visual memory encoding in humans. *Brain Stimulation* **14**, 131–140 (2021).
11. Coleshill, S. G. *et al.* Material-Specific Recognition Memory Deficits Elicited by Unilateral Hippocampal Electrical Stimulation. *J Neurosci* **24**, 1612–1616 (2004).
12. Lacruz, M. E. *et al.* Single pulse electrical stimulation of the hippocampus is sufficient to impair human episodic memory. *Neuroscience* **170**, 623–632 (2010).
13. Fell, J. *et al.* Memory modulation by weak synchronous deep brain stimulation: a pilot study. *Brain Stimul* **6**, 270–273 (2013).
14. Jun, S., Kim, J. S. & Chung, C. K. Direct Stimulation of Human Hippocampus During Verbal Associative Encoding Enhances Subsequent Memory Recollection. *Front Hum Neurosci* **13**, 23 (2019).
15. Hansen, N. *et al.* Memory encoding-related anterior hippocampal potentials are modulated by deep brain stimulation of the entorhinal area. *Hippocampus* **28**, 12–17 (2018).
16. Hampson, R. E. *et al.* Developing a hippocampal neural prosthetic to facilitate human memory encoding and recall. *J Neural Eng* **15**, 036014 (2018).
17. Inman, C. S. *et al.* Direct electrical stimulation of the amygdala enhances declarative memory in humans. *PNAS* **115**, 98–103 (2018).
18. Ezzyat, Y. *et al.* Closed-loop stimulation of temporal cortex rescues functional networks and improves memory. *Nat Commun* **9**, 365 (2018).
19. Kahana, M. J. *et al.* Biomarker-guided neuromodulation aids memory in traumatic brain injury. *medRxiv* 2021.05.18.21256980 (2021) doi:10.1101/2021.05.18.21256980.
20. Koubeissi, M. Z., Kahriman, E., Syed, T. U., Miller, J. & Durand, D. M. Low-frequency electrical stimulation of a fiber tract in temporal lobe epilepsy. *Ann Neurol* **74**, 223–231 (2013).
21. Miller, J. P. *et al.* Visual-spatial memory may be enhanced with theta burst deep brain stimulation of the fornix: a preliminary investigation with four cases. *Brain* **138**, 1833–1842 (2015).
22. Alagapan, S., Lustenberger, C., Hadar, E., Shin, H. W. & Fröhlich, F. Low-frequency direct cortical stimulation of left superior frontal gyrus enhances working memory performance. *NeuroImage* **184**, 697–706 (2019).
23. Natu, V. S. *et al.* Stimulation of the Posterior Cingulate Cortex Impairs Episodic

Memory Encoding. *J Neurosci* **39**, 7173–7182 (2019).
24. Mankin, E. A. & Fried, I. Modulation of Human Memory by Deep Brain Stimulation of the Entorhinal-Hippocampal Circuitry. *Neuron* **106**, 218–235 (2020).
25. Mann, A. *et al.* Chronic deep brain stimulation in an Alzheimer's disease mouse model enhances memory and reduces pathological hallmarks. *Brain Stimulation* 1–38 (2017) doi:10.1016/j.brs.2017.11.012.
26. Leplus, A. *et al.* Chronic fornix deep brain stimulation in a transgenic Alzheimer's rat model reduces amyloid burden, inflammation, and neuronal loss. *Brain Struct Funct* **224**, 363–372 (2019).
27. Zhang, C., Hu, W.-H., Wu, D.-L., Zhang, K. & Zhang, J.-G. Behavioral Effects of Deep Brain Stimulation of the Anterior Nucleus of Thalamus, Entorhinal Cortex and Fornix in a Rat Model of Alzheimer's Disease. *Chin Med J (Engl)* **128**, 1190–1195 (2015).
28. Hao, S. *et al.* Forniceal deep brain stimulation rescues hippocampal memory in Rett syndrome mice. *Nature* **526**, 430–434 (2015).
29. Akwa, Y. *et al.* Synaptic activity protects against AD and FTD-like pathology via autophagic-lysosomal degradation. *Mol Psychiatry* **23**, 1530–1540 (2018).
30. Senova, S., Fomenko, A., Gondard, E. & Lozano, A. M. Anatomy and function of the fornix in the context of its potential as a therapeutic target. *J Neurol Neurosurg Psychiatry* **91**, 547–559 (2020).
31. Colgin, L. L. Rhythms of the hippocampal network. *Nature Rev. Neurosc.* 1–11 (2016) doi:10.1038/nrn.2016.21.
32. Colgin, L. L. *et al.* Frequency of gamma oscillations routes flow of information in the hippocampus. *Nature* **462**, 353–357 (2009).
33. Bieri, K. W., Bobbitt, K. N. & Colgin, L. L. Slow and fast γ rhythms coordinate different spatial coding modes in hippocampal place cells. *Neuron* **82**, 670–681 (2014).
34. Small, S. A., Schobel, S. A., Buxton, R. B., Witter, M. P. & Barnes, C. A. A pathophysiological framework of hippocampal dysfunction in ageing and disease. *Nat Rev Neurosci* **12**, 585–601 (2011).
35. Carmichael, S. T. Rodent models of focal stroke: Size, mechanism, and purpose. *NeuroRX* **2**, 396–409 (2005).
36. Turner, R. C. *et al.* Elucidating the severity of preclinical traumatic brain injury models: a role for functional assessment? *Neurosurgery* **74**, 382–394; discussion 394 (2014).
37. Azouvi, P., Arnould, A., Dromer, E. & Vallat-Azouvi, C. Neuropsychology of traumatic brain injury: An expert overview. *Revue Neurologique* **173**, 461–472 (2017).
38. Piolino, P. *et al.* Autobiographical memory, the sense of recollection and executive functions after severe traumatic brain injury. *Cortex* **43**, 176–195 (2007).
39. Mioni, G., Rendell, P. G., Terrett, G. & Stablum, F. Prospective Memory Performance in Traumatic Brain Injury Patients: A Study of Implementation Intentions. *Journal of the International Neuropsychological Society* **21**, 305–313 (2015).
40. Bohnen, N. *et al.* Late outcome of mild head injury: Results from a controlled postal survey. *Brain Injury* **8**, 701–708 (1994).
41. Prince, C. & Bruhns, M. E. Evaluation and Treatment of Mild Traumatic Brain Injury: The Role of Neuropsychology. *Brain Sci* **7**, (2017).
42. Bigler, E. D. *et al.* Hippocampal volume in normal aging and traumatic brain injury. *AJNR Am J Neuroradiol* **18**, 11–23 (1997).
43. Tate, D. F. & Bigler, E. D. Fornix and hippocampal atrophy in traumatic brain injury. *Learn. Mem.* **7**, 442–446 (2000).
44. Palacios, E. M. *et al.* Long-term declarative memory deficits in diffuse TBI: correlations with cortical thickness, white matter integrity and hippocampal volume. *Cortex* **49**, 646–657 (2013).

45. Ariza, M. *et al.* Hippocampal head atrophy after traumatic brain injury. *Neuropsychologia* **44**, 1956–1961 (2006).
46. Strich, SabinaJ. SHEARING OF NERVE FIBRES AS A CAUSE OF BRAIN DAMAGE DUE TO HEAD INJURY: A Pathological Study of Twenty Cases. *The Lancet* **278**, 443–448 (1961).
47. Bigler, E. D. Neuropathology of Mild Traumatic Brain Injury: Correlation to Neurocognitive and Neurobehavioral Findings. in *Brain Neurotrauma: Molecular, Neuropsychological, and Rehabilitation Aspects* (ed. Kobeissy, F. H.) (CRC Press/Taylor & Francis, 2015).
48. Henry-Feugeas, M. C. *et al.* MRI analysis of brain atrophy after severe closed-head injury: relation to clinical status. *Brain Inj* **14**, 597–604 (2000).
49. Sharp, D. J. & Ham, T. E. Investigating white matter injury after mild traumatic brain injury. *Curr. Opin. Neurol.* **24**, 558–563 (2011).
50. Little, D. M. *et al.* Thalamic integrity underlies executive dysfunction in traumatic brain injury. *Neurology* **74**, 558–564 (2010).
51. Sharp, D. J., Scott, G. & Leech, R. Network dysfunction after traumatic brain injury. *Nat Rev Neurol* **10**, 156–166 (2014).
52. Rigon, A., Duff, M. C., McAuley, E., Kramer, A. F. & Voss, M. W. Is Traumatic Brain Injury Associated with Reduced Inter-Hemispheric Functional Connectivity? A Study of Large-Scale Resting State Networks following Traumatic Brain Injury. *J. Neurotrauma* **33**, 977–989 (2016).
53. Dixon, C. E., Clifton, G. L., Lighthall, J. W., Yaghmai, A. A. & Hayes, R. L. A controlled cortical impact model of traumatic brain injury in the rat. *Journal of Neuroscience Methods* **39**, 253–262 (1991).
54. Washington, P. M. *et al.* The Effect of Injury Severity on Behavior: A Phenotypic Study of Cognitive and Emotional Deficits after Mild, Moderate, and Severe Controlled Cortical Impact Injury in Mice. *J Neurotrauma* **29**, 2283–2296 (2012).
55. Scheff, S. W., Baldwin, S. A., Brown, R. W. & Kraemer, P. J. Morris Water Maze Deficits in Rats following Traumatic Brain Injury: Lateral Controlled Cortical Impact. *Journal of Neurotrauma* **14**, 615–627 (1997).
56. Osier, N. D. & Dixon, C. E. The Controlled Cortical Impact Model: Applications, Considerations for Researchers, and Future Directions. *Front. Neurol.* **7**, (2016).
57. Pleasant, J. M. *et al.* Rate of Neurodegeneration in the Mouse Controlled Cortical Impact Model Is Influenced by Impactor Tip Shape: Implications for Mechanistic and Therapeutic Studies. *J Neurotrauma* **28**, 2245–2262 (2011).
58. Floyd, C. L., Golden, K. M., Black, R. T., Hamm, R. J. & Lyeth, B. G. Craniectomy Position Affects Morris Water Maze Performance and Hippocampal Cell Loss after Parasagittal Fluid Percussion. *Journal of Neurotrauma* **19**, 303–316 (2002).
59. Cernak, I. Animal models of head trauma. *Neurotherapeutics* **2**, 410–422 (2005).
60. McIntosh, T. K. *et al.* Traumatic brain injury in the rat: Characterization of a lateral fluid-percussion model. *Neuroscience* **28**, 233–244 (1989).
61. Saatman, K. E., Feeko, K. J., Pape, R. L. & Raghupathi, R. Differential behavioral and histopathological responses to graded cortical impact injury in mice. *J. Neurotrauma* **23**, 1241–1253 (2006).
62. Pierce, J. E., Smith, D. H., Trojanowski, J. Q. & McIntosh, T. K. Enduring cognitive, neurobehavioral and histopathological changes persist for up to one year following severe experimental brain injury in rats. *Neuroscience* **87**, 359–369 (1998).
63. Smith, D. H. *et al.* Progressive Atrophy and Neuron Death for One Year Following Brain Trauma in the Rat. *Journal of Neurotrauma* **14**, 715–727 (1997).
64. Lowenstein, D. H., Thomas, M. J., Smith, D. H. & McIntosh, T. K. Selective

vulnerability of dentate hilar neurons following traumatic brain injury: a potential mechanistic link between head trauma and disorders of the hippocampus. *J. Neurosci.* **12**, 4846–4853 (1992).
65. Hicks, R. R., Smith, D. H., Lowenstein, D. H., Marie, R. S. & McINTOSH, T. K. Mild Experimental Brain Injury in the Rat Induces Cognitive Deficits Associated with Regional Neuronal Loss in the Hippocampus. *Journal of Neurotrauma* **10**, 405–414 (1993).
66. Cantu, D. *et al.* Traumatic Brain Injury Increases Cortical Glutamate Network Activity by Compromising GABAergic Control. *Cereb. Cortex* **25**, 2306–2320 (2015).
67. Hallam, T. M. *et al.* Comparison of behavioral deficits and acute neuronal degeneration in rat lateral fluid percussion and weight-drop brain injury models. *J. Neurotrauma* **21**, 521–539 (2004).
68. Winston, C. N. *et al.* Controlled Cortical Impact Results in an Extensive Loss of Dendritic Spines that Is Not Mediated by Injury-Induced Amyloid-Beta Accumulation. *J Neurotrauma* **30**, 1966–1972 (2013).
69. Smith, C. J., Xiong, G., Elkind, J. A., Putnam, B. & Cohen, A. S. Brain Injury Impairs Working Memory and Prefrontal Circuit Function. *Front Neurol* **6**, 240 (2015).
70. Clausen, F. *et al.* Correlation of hippocampal morphological changes and morris water maze performance after cortical contusion injury in rats. *Neurosurgery* **57**, 154–163; discussion 154-163 (2005).
71. Anderson, K. J., Miller, K. M., Fugaccia, I. & Scheff, S. W. Regional distribution of Fluoro-Jade B staining in the hippocampus following traumatic brain injury. *Experimental Neurology* **193**, 125–130 (2005).
72. Baldwin, S. A. *et al.* Neuronal Cell Loss in the CA3 Subfield of the Hippocampus Following Cortical Contusion Utilizing the Optical Disector Method for Cell Counting. *Journal of Neurotrauma* **14**, 385–398 (1997).
73. Scheff, S. W. *et al.* Synaptogenesis in the hippocampal CA1 field following traumatic brain injury. *J. Neurotrauma* **22**, 719–732 (2005).
74. Smith, D. H., Okiyama, K., Thomas, M. J., Claussen, B. & McIntosh, T. K. Evaluation of memory dysfunction following experimental brain injury using the Morris water maze. *J. Neurotrauma* **8**, 259–269 (1991).
75. Singleton, R. H., Yan, H. Q., Fellows-Mayle, W. & Dixon, C. E. Resveratrol attenuates behavioral impairments and reduces cortical and hippocampal loss in a rat controlled cortical impact model of traumatic brain injury. *J. Neurotrauma* **27**, 1091–1099 (2010).
76. Frankowski, J. C., Kim, Y. J. & Hunt, R. F. Selective vulnerability of hippocampal interneurons to graded traumatic brain injury. *Neurobiology of Disease* (2018) doi:10.1016/j.nbd.2018.07.022.
77. Almeida-Suhett, C. P. *et al.* GABAergic interneuronal loss and reduced inhibitory synaptic transmission in the hippocampal CA1 region after mild traumatic brain injury. *Experimental Neurology* **273**, 11–23 (2015).
78. Toth, Z., Hollrigel, G. S., Gorcs, T. & Soltesz, I. Instantaneous Perturbation of Dentate Interneuronal Networks by a Pressure Wave-Transient Delivered to the Neocortex. *The Journal of Neuroscience* **17**, 8106–8117 (1997).
79. Huusko, N., Römer, C., Ndode-Ekane, X. E., Lukasiuk, K. & Pitkänen, A. Loss of hippocampal interneurons and epileptogenesis: a comparison of two animal models of acquired epilepsy. *Brain Struct Funct* **220**, 153–191 (2015).
80. Pavlov, I. *et al.* Progressive loss of phasic, but not tonic, GABAA receptor-mediated inhibition in dentate granule cells in a model of post-traumatic epilepsy in rats. *Neuroscience* **194**, 208–219 (2011).
81. Hall, E. D., Bryant, Y. D., Cho, W. & Sullivan, P. G. Evolution of Post-Traumatic

Neurodegeneration after Controlled Cortical Impact Traumatic Brain Injury in Mice and Rats as Assessed by the De Olmos Silver and Fluorojade Staining Methods. *Journal of Neurotrauma* **25**, 235–247 (2008).
82. Lyeth, B. G., Gong, Q. Z., Shields, S., Muizelaar, J. P. & Berman, R. F. Group I metabotropic glutamate antagonist reduces acute neuronal degeneration and behavioral deficits after traumatic brain injury in rats. *Exp. Neurol.* **169**, 191–199 (2001).
83. Hunt, R. F., Scheff, S. W. & Smith, B. N. Synaptic Reorganization of Inhibitory Hilar Interneuron Circuitry after Traumatic Brain Injury in Mice. *Journal of Neuroscience* **31**, 6880–6890 (2011).
84. Haug, F.-M. \vSmejda. Light microscopical mapping of the hippocampal region, the pyriform cortex and the corticomedial amygdaloid nuclei of the rat with Timm's sulphide silver method. *Zeitschrift für Anatomie und Entwicklungsgeschichte* **145**, 1–27 (1974).
85. Buckmaster, P. S. Mossy Fiber Sprouting in the Dentate Gyrus. in *Jasper's Basic Mechanisms of the Epilepsies* 29 (National Center for Biotechnology Information, 2012).
86. Chen, Y., Mao, H., Yang, K. H., Abel, T. & Meaney, D. F. A Modified Controlled Cortical Impact Technique to Model Mild Traumatic Brain Injury Mechanics in Mice. *Front. Neurol.* **5**, (2014).
87. Cortez, S. C., McIntosh, T. K. & Noble, L. J. Experimental fluid percussion brain injury: vascular disruption and neuronal and glial alterations. *Brain Res* **482**, 271–282 (1989).
88. Carbonell, W. S. & Grady, M. S. Regional and temporal characterization of neuronal, glial, and axonal response after traumatic brain injury in the mouse. *Acta Neuropathol.* **98**, 396–406 (1999).
89. Immonen, R. J., Kharatishvili, I., Gröhn, H., Pitkänen, A. & Gröhn, O. H. J. Quantitative MRI predicts long-term structural and functional outcome after experimental traumatic brain injury. *Neuroimage* **45**, 1–9 (2009).
90. Sinson, G., Perri, B. R., Trojanowski, J. Q., Flamm, E. S. & McIntosh, T. K. Improvement of cognitive deficits and decreased cholinergic neuronal cell loss and apoptotic cell death following neurotrophin infusion after experimental traumatic brain injury. *Journal of Neurosurgery* **86**, 511–518 (1997).
91. Hall, E. D. *et al.* Spatial and temporal characteristics of neurodegeneration after controlled cortical impact in mice: more than a focal brain injury. *J. Neurotrauma* **22**, 252–265 (2005).
92. Hayward, N. M. E. A. *et al.* Association of chronic vascular changes with functional outcome after traumatic brain injury in rats. *J. Neurotrauma* **27**, 2203–2219 (2010).
93. Dixon, C. E. *et al.* One-year study of spatial memory performance, brain morphology, and cholinergic markers after moderate controlled cortical impact in rats. *J. Neurotrauma* **16**, 109–122 (1999).
94. Nonaka, M. *et al.* Prolonged activation of NF-kappaB following traumatic brain injury in rats. *J. Neurotrauma* **16**, 1023–1034 (1999).
95. Glushakova, O. Y., Johnson, D. & Hayes, R. L. Delayed increases in microvascular pathology after experimental traumatic brain injury are associated with prolonged inflammation, blood-brain barrier disruption, and progressive white matter damage. *J. Neurotrauma* **31**, 1180–1193 (2014).
96. Donovan, V. *et al.* Repeated mild traumatic brain injury results in long-term white-matter disruption. *J. Cereb. Blood Flow Metab.* **34**, 715–723 (2014).
97. Fox, G. B., Fan, L., Levasseur, R. A. & Faden, A. I. Sustained sensory/motor and cognitive deficits with neuronal apoptosis following controlled cortical impact brain injury in the mouse. *J. Neurotrauma* **15**, 599–614 (1998).
98. Robinson, S. *et al.* Extended Erythropoietin Treatment Prevents Chronic Executive

Functional and Microstructural Deficits Following Early Severe Traumatic Brain Injury in Rats. *Front. Neurol.* **9**, 451 (2018).
99. Lyeth, B. G. *et al.* Prolonged memory impairment in the absence of hippocampal cell death following traumatic brain injury in the rat. *Brain Res.* **526**, 249–258 (1990).
100. Hamm, R. J., Lyeth, B. G., Jenkins, L. W., O'Dell, D. M. & Pike, B. R. Selective cognitive impairment following traumatic brain injury in rats. *Behav. Brain Res.* **59**, 169–173 (1993).
101. Zhao, Z., Loane, D. J., Murray, M. G., Stoica, B. A. & Faden, A. I. Comparing the Predictive Value of Multiple Cognitive, Affective, and Motor Tasks after Rodent Traumatic Brain Injury. *J Neurotrauma* **29**, 2475–2489 (2012).
102. Marklund, N. *et al.* Cognitive outcome following brain injury and treatment with an inhibitor of Nogo-A in association with an attenuated downregulation of hippocampal growth-associated protein-43 expression. *J. Neurosurg.* **107**, 844–853 (2007).
103. Lima, F. D. *et al.* Na+,K+-ATPase activity impairment after experimental traumatic brain injury: relationship to spatial learning deficits and oxidative stress. *Behav. Brain Res.* **193**, 306–310 (2008).
104. Lee, D. J. *et al.* Septohippocampal Neuromodulation Improves Cognition after Traumatic Brain Injury. *Journal of Neurotrauma* **32**, 1822–1832 (2015).
105. Fedor, M., Berman, R. F., Muizelaar, J. P. & Lyeth, B. G. Hippocampal θ dysfunction after lateral fluid percussion injury. *J. Neurotrauma* **27**, 1605–1615 (2010).
106. Scafidi, S., Racz, J., Hazelton, J., McKenna, M. C. & Fiskum, G. Neuroprotection by Acetyl-L-Carnitine after Traumatic Injury to the Immature Rat Brain. *Developmental Neuroscience* (2011) doi:10.1159/000323178.
107. Hamm, R. J. *et al.* Cognitive Deficits Following Traumatic Brain Injury Produced by Controlled Cortical Impact. *Journal of Neurotrauma* **9**, 11–20 (1992).
108. Sargolzaei, S. *et al.* Craniectomy, Alterations in fMRI Functional Connectivity and Cognitive Performance in Developmental Model of TBI. *Conf Proc IEEE Eng Med Biol Soc* **2018**, 5414–5417 (2018).
109. Lifshitz, J., Witgen, B. & Grady, M. Acute cognitive impairment after lateral fluid percussion brain injury recovers by 1 month: Evaluation by conditioned fear response. *Behavioural Brain Research* **177**, 347–357 (2007).
110. Smith, D. H., Okiyama, K., Thomas, M. J., Claussen, B. & McINTOSH, T. K. Evaluation of Memory Dysfunction Following Experimental Brain Injury Using the Morris Water Maze. *Journal of Neurotrauma* **8**, 259–269 (1991).
111. Whiting, M. D. & Hamm, R. J. Mechanisms of anterograde and retrograde memory impairment following experimental traumatic brain injury. *Brain Research* **1213**, 69–77 (2008).
112. Hamm, R. J. *et al.* Working memory deficits following traumatic brain injury in the rat. *J. Neurotrauma* **13**, 317–323 (1996).
113. Whiting, M. D. & Hamm, R. J. Traumatic Brain Injury Produces Delay-Dependent Memory Impairment in Rats. *Journal of Neurotrauma* **23**, 1529–1534 (2006).
114. Eakin, K. & Miller, J. P. Mild Traumatic Brain Injury Is Associated with Impaired Hippocampal Spatiotemporal Representation in the Absence of Histological Changes. *Journal of Neurotrauma* **29**, 1180–1187 (2012).
115. Thompson, H. J. *et al.* Cognitive evaluation of traumatically brain-injured rats using serial testing in the Morris water maze. *Restor Neurol Neurosci* **24**, 109–114 (2006).
116. Shultz, S. R. *et al.* Repeated Mild Lateral Fluid Percussion Brain Injury in the Rat Causes Cumulative Long-Term Behavioral Impairments, Neuroinflammation, and Cortical Loss in an Animal Model of Repeated Concussion. *Journal of Neurotrauma* **29**, 281–294 (2012).

117. Sanders, M. J., Dietrich, W. D. & Green, E. J. Cognitive function following traumatic brain injury: effects of injury severity and recovery period in a parasagittal fluid-percussive injury model. *J. Neurotrauma* **16**, 915–925 (1999).
118. Hoskison, M. M. *et al.* Persistent working memory dysfunction following traumatic brain injury: evidence for a time-dependent mechanism. *Neuroscience* **159**, 483–491 (2009).
119. Dawish, H., Mahmood, A., Schallert, T., Chopp, M. & Therrien, B. Mild traumatic brain injury (MTBI) leads to spatial learning deficits. *Brain Inj* **26**, 151–165 (2012).
120. Heitger, M. H. *et al.* Motor deficits and recovery during the first year following mild closed head injury. *Brain Injury* **20**, 807–824 (2006).
121. Smith, D. H. *et al.* A Model of Parasagittal Controlled Cortical Impact in the Mouse: Cognitive and Histopathologic Effects. *Journal of Neurotrauma* **12**, 169–178 (1995).
122. McNamara, K. C. S., Lisembee, A. M. & Lifshitz, J. The Whisker Nuisance Task Identifies a Late-Onset, Persistent Sensory Sensitivity in Diffuse Brain-Injured Rats. *Journal of Neurotrauma* **27**, 695–706 (2010).
123. Steuer, E., Schaefer, M. L. & Belluscio, L. Using the Olfactory System as an In Vivo Model To Study Traumatic Brain Injury and Repair. *J Neurotrauma* **31**, 1277–1291 (2014).
124. Ping, X. & Jin, X. Transition from Initial Hypoactivity to Hyperactivity in Cortical Layer V Pyramidal Neurons after Traumatic Brain Injury *In Vivo*. *Journal of Neurotrauma* **33**, 354–361 (2016).
125. Hånell, A., Greer, J. E. & Jacobs, K. M. Increased Network Excitability Due to Altered Synaptic Inputs to Neocortical Layer V Intact and Axotomized Pyramidal Neurons after Mild Traumatic Brain Injury. *J Neurotrauma* **32**, 1590–1598 (2015).
126. Carron, S. F., Alwis, D. S. & Rajan, R. Traumatic Brain Injury and Neuronal Functionality Changes in Sensory Cortex. *Front Syst Neurosci* **10**, 47 (2016).
127. Johnstone, V. P. A. *et al.* Experimental Traumatic Brain Injury Results in Long-Term Recovery of Functional Responsiveness in Sensory Cortex but Persisting Structural Changes and Sensorimotor, Cognitive, and Emotional Deficits. *Journal of Neurotrauma* **32**, 1333–1346 (2015).
128. von Baumgarten, L., Trabold, R., Thal, S., Back, T. & Plesnila, N. Role of Cortical Spreading Depressions for Secondary Brain Damage after Traumatic Brain Injury in Mice. *J Cereb Blood Flow Metab* **28**, 1353–1360 (2008).
129. Sawant-Pokam, P. M., Suryavanshi, P., Mendez, J. M., Dudek, F. E. & Brennan, K. C. Mechanisms of Neuronal Silencing After Cortical Spreading Depression. *Cerebral Cortex* **27**, (2016).
130. Kobori, N. & Dash, P. K. Reversal of Brain Injury-Induced Prefrontal Glutamic Acid Decarboxylase Expression and Working Memory Deficits by D1 Receptor Antagonism. *J. Neurosci.* **26**, 4236–4246 (2006).
131. Le Prieult, F., Thal, S. C., Engelhard, K., Imbrosci, B. & Mittmann, T. Acute Cortical Transhemispheric Diaschisis after Unilateral Traumatic Brain Injury. *Journal of Neurotrauma* **34**, 1097–1110 (2017).
132. Verley, D. R. *et al.* Remote Changes in Cortical Excitability after Experimental Traumatic Brain Injury and Functional Reorganization. *Journal of Neurotrauma* **35**, 2448–2461 (2018).
133. Harris, N. G., Chen, S.-F. & Pickard, J. D. Cortical Reorganization after Experimental Traumatic Brain Injury: A Functional Autoradiography Study. *Journal of Neurotrauma* **30**, 1137–1146 (2013).
134. Holschneider, D. P., Guo, Y., Wang, Z., Roch, M. & Scremin, O. U. Remote Brain Network Changes after Unilateral Cortical Impact Injury and Their Modulation by Acetylcholinesterase Inhibition. *J Neurotrauma* **30**, 907–919 (2013).
135. Mishra, A. M. *et al.* Decreased Resting Functional Connectivity after Traumatic Brain

Injury in the Rat. *PLoS ONE* **9**, e95280 (2014).
136. Harris, N. G. *et al.* Disconnection and hyper-connectivity underlie reorganization after TBI: A rodent functional connectomic analysis. *Experimental Neurology* **277**, 124–138 (2016).
137. Reid, A. Y., Bragin, A., Giza, C. C., Staba, R. J. & Engel, J. The progression of electrophysiologic abnormalities during epileptogenesis after experimental traumatic brain injury. *Epilepsia* **57**, 1558–1567 (2016).
138. Kao, C. *et al.* Suppression of thalamocortical oscillations following traumatic brain injury in rats: Laboratory investigation. *Journal of Neurosurgery* **117**, 316–323 (2012).
139. Deng, P. & Xu, Z. C. Contribution of Ih to Neuronal Damage in the Hippocampus after Traumatic Brain Injury in Rats. *Journal of Neurotrauma* **28**, 1173–1183 (2011).
140. Santhakumar, V. *et al.* Granule cell hyperexcitability in the early post-traumatic rat dentate gyrus: the 'irritable mossy cell' hypothesis. *J. Physiol. (Lond.)* **524 Pt 1**, 117–134 (2000).
141. Lei, Z., Deng, P., Li, J. & Xu, Z. C. Alterations of A-Type Potassium Channels in Hippocampal Neurons after Traumatic Brain Injury. *Journal of Neurotrauma* **29**, 235–245 (2012).
142. Folweiler, K. A., Samuel, S., Metheny, H. E. & Cohen, A. S. Diminished Dentate Gyrus Filtering of Cortical Input Leads to Enhanced Area Ca3 Excitability after Mild Traumatic Brain Injury. *Journal of Neurotrauma* **35**, 1304–1317 (2018).
143. Hunt, R. F., Scheff, S. W. & Smith, B. N. Regionally Localized Recurrent Excitation in the Dentate Gyrus of a Cortical Contusion Model of Posttraumatic Epilepsy. *Journal of Neurophysiology* **103**, 1490–1500 (2010).
144. Butler, C. R., Boychuk, J. A. & Smith, B. N. Differential effects of rapamycin treatment on tonic and phasic GABAergic inhibition in dentate granule cells after focal brain injury in mice. *Exp Neurol* **280**, 30–40 (2016).
145. Mtchedlishvili, Z. *et al.* Increase of GABAA receptor-mediated tonic inhibition in dentate granule cells after traumatic brain injury. *Neurobiol. Dis.* **38**, 464–475 (2010).
146. Gao, X., Deng, P., Xu, Z. C. & Chen, J. Moderate Traumatic Brain Injury Causes Acute Dendritic and Synaptic Degeneration in the Hippocampal Dentate Gyrus. *PLoS One* **6**, (2011).
147. D'Ambrosio, R., Maris, D. O., Grady, M. S., Winn, H. R. & Janigro, D. Selective loss of hippocampal long-term potentiation, but not depression, following fluid percussion injury. *Brain Research* **786**, 64–79 (1998).
148. Miyazaki, S. *et al.* Enduring suppression of hippocampal long-term potentiation following traumatic brain injury in rat. *Brain Research* **585**, 335–339 (1992).
149. Reeves, ThomasM., Lyeth, BruceG. & Povlishock, JohnT. Long-term potentiation deficits and excitability changes following traumatic brain injury. *Experimental Brain Research* **106**, (1995).
150. White, E. R., Pinar, C., Bostrom, C. A., Meconi, A. & Christie, B. R. Mild Traumatic Brain Injury Produces Long-Lasting Deficits in Synaptic Plasticity in the Female Juvenile Hippocampus. *Journal of Neurotrauma* **34**, 1111–1123 (2017).
151. Yamashita, S., Hasuo, H., Tokutomi, T., Shigemori, M. & Akasu, T. Edaravone Attenuates Impairment of Synaptic Plasticity in Granule Cell Layer of the Dentate Gyrus Following Traumatic Brain Injury. *Kurume Med. J.* **58**, 47–58 (2011).
152. Albensi, B. C., Sullivan, P. G., Thompson, M. B., Scheff, S. W. & Mattson, M. P. Cyclosporin Ameliorates Traumatic Brain-Injury-Induced Alterations of Hippocampal Synaptic Plasticity. *Experimental Neurology* **162**, 385–389 (2000).
153. Sick, T. J., Pérez-Pinzón, M. A. & Feng, Z.-Z. Impaired expression of long-term potentiation in hippocampal slices 4 and 48 h following mild fluid-percussion brain injury in

vivo. *Brain Research* **785**, 287–292 (1998).
154. Schwarzbach, E., Bonislawski, D. P., Xiong, G. & Cohen, A. S. Mechanisms underlying the inability to induce area CA1 LTP in the mouse after traumatic brain injury. *Hippocampus* **16**, 541–550 (2006).
155. Sanders, M. J., Sick, T. J., Perez-Pinzon, M. A., Dietrich, W. D. & Green, E. J. Chronic failure in the maintenance of long-term potentiation following fluid percussion injury in the rat. *Brain Research* **861**, 69–76 (2000).
156. Norris, C. M. & Scheff, S. W. Recovery of Afferent Function and Synaptic Strength in Hippocampal CA1 following Traumatic Brain Injury. *Journal of Neurotrauma* **26**, 2269–2278 (2009).
157. Paterno, R., Metheny, H., Xiong, G., Elkind, J. & Cohen, A. S. Mild Traumatic Brain Injury Decreases Broadband Power in Area CA1. *J. Neurotrauma* **33**, 1645–1649 (2016).
158. D'Ambrosio, R. Progression from frontal-parietal to mesial-temporal epilepsy after fluid percussion injury in the rat. *Brain* **128**, 174–188 (2004).
159. Bolkvadze, T. & Pitkänen, A. Development of Post-Traumatic Epilepsy after Controlled Cortical Impact and Lateral Fluid-Percussion-Induced Brain Injury in the Mouse. *Journal of Neurotrauma* **29**, 789–812 (2012).
160. D'Ambrosio, R. & Miller, J. W. What Is an Epileptic Seizure? Unifying Definitions in Clinical Practice and Animal Research to Develop Novel Treatments. *Epilepsy Currents* **10**, 61 (2010).
161. Dudek, F. E. & Bertram, E. H. Counterpoint to "What Is an Epileptic Seizure?" By D'Ambrosio and Miller. *Epilepsy Curr* **10**, 91–94 (2010).
162. Carballosa Gonzalez, M. M., Blaya, M. O., Alonso, O. F., Bramlett, H. M. & Hentall, I. D. Midbrain Raphe Stimulation Improves Behavioral and Anatomical Recovery from Fluid-Percussion Brain Injury. *J Neurotrauma* **30**, 119–130 (2013).
163. Sweet, J. A., Eakin, K. C., Munyon, C. N. & Miller, J. P. Improved learning and memory with theta-burst stimulation of the fornix in rat model of traumatic brain injury. *Hippocampus* **24**, 1592–1600 (2014).
164. Chan, H. H. *et al.* Lateral Cerebellar Nucleus Stimulation has Selective Effects on Glutamatergic and GABAergic Perilesional Neurogenesis After Cortical Ischemia in the Rodent Model. *Neurosurgery* **83**, 1057–1067 (2018).
165. Smith, D. C. *et al.* Electrical Stimulation of the Vagus Nerve Enhances Cognitive and Motor Recovery following Moderate Fluid Percussion Injury in the Rat. *Journal of Neurotrauma* **22**, 1485–1502 (2005).
166. Yoon, K. J., Lee, Y.-T., Chae, S. W., Park, C. R. & Kim, D. Y. Effects of anodal transcranial direct current stimulation (tDCS) on behavioral and spatial memory during the early stage of traumatic brain injury in the rats. *Journal of the Neurological Sciences* **362**, 314–320 (2016).
167. Shin, S. S. *et al.* Transcranial magnetic stimulation and environmental enrichment enhances cortical excitability and functional outcomes after traumatic brain injury. *Brain Stimul* **11**, 1306–1313 (2018).
168. Lu, H. *et al.* Transcranial magnetic stimulation facilitates neurorehabilitation after pediatric traumatic brain injury. *Sci Rep* **5**, 14769 (2015).
169. Shapira, Y. *et al.* Experimental closed head injury in rats: mechanical, pathophysiologic, and neurologic properties. *Crit. Care Med.* **16**, 258–265 (1988).
170. Marmarou, A. *et al.* A new model of diffuse brain injury in rats: Part I: Pathophysiology and biomechanics. *Journal of Neurosurgery* **80**, 291–300 (1994).
171. Sauerbeck, A. D. *et al.* modCHIMERA: a novel murine closed-head model of moderate traumatic brain injury. *Scientific Reports* **8**, 7677 (2018).
172. Bailey, Z. S., Hubbard, W. B. & VandeVord, P. J. Cellular Mechanisms and

Behavioral Outcomes in Blast-Induced Neurotrauma: Comparing Experimental Setups. in *Injury Models of the Central Nervous System* (eds. Kobeissy, F. H., Dixon, C. E., Hayes, R. L. & Mondello, S.) vol. 1462 119–138 (Springer New York, 2016).
173. Needham, C. E., Ritzel, D., Rule, G. T., Wiri, S. & Young, L. Blast Testing Issues and TBI: Experimental Models That Lead to Wrong Conclusions. *Front Neurol* **6**, 72 (2015).
174. DeWitt, D. S. & Prough, D. S. Blast-Induced Brain Injury and Posttraumatic Hypotension and Hypoxemia. *Journal of Neurotrauma* **26**, 877–887 (2009).
175. Long, J. B. *et al.* Blast Overpressure in Rats: Recreating a Battlefield Injury in the Laboratory. *Journal of Neurotrauma* **26**, 827–840 (2009).
176. Kuehn, R. *et al.* Rodent Model of Direct Cranial Blast Injury. *Journal of Neurotrauma* **28**, 2155–2169 (2011).
177. Hsieh, T.-H. *et al.* Relationship of mechanical impact magnitude to neurologic dysfunction severity in a rat traumatic brain injury model. *PLoS ONE* **12**, e0178186 (2017).
178. Perez-Polo, J. R. *et al.* A rodent model of mild traumatic brain blast injury: Blast mTBI Model. *Journal of Neuroscience Research* **93**, 549–561 (2015).
179. Foda, M. A. A.-E. & Marmarou, A. A new model of diffuse brain injury in rats: Part II: Morphological characterization. *Journal of Neurosurgery* **80**, 301–313 (1994).
180. Carron, S. F., Yan, E. B., Allitt, B. J. & Rajan, R. Immediate and Medium-term Changes in Cortical and Hippocampal Inhibitory Neuronal Populations after Diffuse TBI. *Neuroscience* **388**, 152–170 (2018).
181. Cheng, J. *et al.* Development of a rat model for studying blast-induced traumatic brain injury. *Journal of the Neurological Sciences* **294**, 23–28 (2010).
182. Tang, Y. P., Noda, Y., Hasegawa, T. & Nabeshima, T. A concussive-like brain injury model in mice (II): selective neuronal loss in the cortex and hippocampus. *J. Neurotrauma* **14**, 863–873 (1997).
183. Henninger, N. *et al.* Impaired spatial learning in a novel rat model of mild cerebral concussion injury. *Experimental Neurology* **195**, 447–457 (2005).
184. Ning, Y.-L. Chronic caffeine exposure attenuates blast-induced memory deficit in mice. *Chinese Journal of Traumatology* 8 (2015).
185. Budde, M. D. *et al.* Primary Blast Traumatic Brain Injury in the Rat: Relating Diffusion Tensor Imaging and Behavior. *Front. Neurol.* **4**, (2013).
186. McAteer, K. M., Corrigan, F., Thornton, E., Turner, R. J. & Vink, R. Short and Long Term Behavioral and Pathological Changes in a Novel Rodent Model of Repetitive Mild Traumatic Brain Injury. *PLoS ONE* **11**, e0160220 (2016).
187. Griesemer, D. & Mautes, A. M. Closed Head Injury Causes Hyperexcitability in Rat Hippocampal CA1 but not in CA3 Pyramidal Cells. *Journal of Neurotrauma* **24**, 1823–1832 (2007).
188. Goldstein, L. *et al.* Chronic Traumatic Encephalopathy in Blast-Exposed Military Veterans and a Blast Neurotrauma Mouse Model. *Science Translational Medicine* **4**, (2012).
189. Yaka, R. *et al.* D-cycloserine improves functional recovery and reinstates long-term potentiation (LTP) in a mouse model of closed head injury. *The FASEB Journal* **21**, 2033–2041 (2007).
190. Creed, J. A., DiLeonardi, A. M., Fox, D. P., Tessler, A. R. & Raghupathi, R. Concussive Brain Trauma in the Mouse Results in Acute Cognitive Deficits and Sustained Impairment of Axonal Function. *J Neurotrauma* **28**, 547–563 (2011).
191. Garman, R. H. *et al.* Blast Exposure in Rats with Body Shielding Is Characterized Primarily by Diffuse Axonal Injury. *Journal of Neurotrauma* **28**, 947–959 (2011).
192. Heldt, S. A. *et al.* A novel closed-head model of mild traumatic brain injury caused by primary overpressure blast to the cranium produces sustained emotional deficits in mice. *Front Neurol* **5**, 2 (2014).

193. Mierzwa, A. J., Marion, C. M., Sullivan, G. M., McDaniel, D. P. & Armstrong, R. C. Components of myelin damage and repair in the progression of white matter pathology after mild traumatic brain injury. *J. Neuropathol. Exp. Neurol.* **74**, 218–232 (2015).
194. Evanson, N. K., Guilhaume-Correa, F., Herman, J. P. & Goodman, M. D. Optic tract injury after closed head traumatic brain injury in mice: A model of indirect traumatic optic neuropathy. *PLoS ONE* **13**, e0197346 (2018).
195. Kikinis, Z. *et al.* Diffusion imaging of mild traumatic brain injury in the impact accelerated rodent model: A pilot study. *Brain Injury* **31**, 1376–1381 (2017).
196. Sullivan, G. M. *et al.* Oligodendrocyte Lineage and Subventricular Zone Response to Traumatic Axonal Injury in the Corpus Callosum. *J Neuropathol Exp Neurol* **72**, 1106–1125 (2013).
197. Guley, N. H. *et al.* A Novel Closed-Head Model of Mild Traumatic Brain Injury Using Focal Primary Overpressure Blast to the Cranium in Mice. *J. Neurotrauma* **33**, 403–422 (2016).
198. Schmidt, R. H., Schoten, K. J. & Maughan, P. H. Cognitive Impairment and Synaptosomal Choline Uptake in Rats Following Impact Acceleration Injury. *Journal of Neurotrauma* **17**, 1129–1139 (2000).
199. Beaumont, A. *et al.* The impact-acceleration model of head injury: injury severity predicts motor and cognitive performance after trauma. *Neurol. Res.* **21**, 742–754 (1999).
200. Lucke-Wold, B. P., Logsdon, A. F., Turner, R. C., Huber, J. D. & Rosen, C. L. Endoplasmic Reticulum Stress Modulation as a Target for Ameliorating Effects of Blast Induced Traumatic Brain Injury. *Journal of Neurotrauma* **34**, S-62-S-70 (2017).
201. Hall, A. A. *et al.* Repeated Low Intensity Blast Exposure Is Associated with Damaged Endothelial Glycocalyx and Downstream Behavioral Deficits. *Front. Behav. Neurosci.* **11**, 104 (2017).
202. Zohar, O. *et al.* Closed-head minimal traumatic brain injury produces long-term cognitive deficits in mice. *Neuroscience* **118**, 949–955 (2003).
203. Ouyang, J. *et al.* Blast-Induced Tinnitus and Elevated Central Auditory and Limbic Activity in Rats: A Manganese-Enhanced MRI and Behavioral Study. *Sci Rep* **7**, 4852 (2017).
204. Elder, G. A. *et al.* Blast Exposure Induces Post-Traumatic Stress Disorder-Related Traits in a Rat Model of Mild Traumatic Brain Injury. *Journal of Neurotrauma* **29**, 2564–2575 (2012).
205. Nichols, J. N., Hagan, K. L. & Floyd, C. L. Evaluation of Touchscreen Chambers To Assess Cognition in Adult Mice: Effect of Training and Mild Traumatic Brain Injury. *J. Neurotrauma* **34**, 2481–2494 (2017).
206. Sarkaki, A. *et al.* Gallic acid improved behavior, brain electrophysiology, and inflammation in a rat model of traumatic brain injury. *Can. J. Physiol. Pharmacol.* **93**, 687–694 (2015).
207. Milman, A., Rosenberg, A., Weizman, R. & Pick, C. G. Mild Traumatic Brain Injury Induces Persistent Cognitive Deficits and Behavioral Disturbances in Mice. *Journal of Neurotrauma* **22**, 1003–1010 (2005).
208. Morawska, M. M. *et al.* Sleep Modulation Alleviates Axonal Damage and Cognitive Decline after Rodent Traumatic Brain Injury. *J. Neurosci.* **36**, 3422–3429 (2016).
209. Walls, M. K. *et al.* Structural and biochemical abnormalities in the absence of acute deficits in mild primary blast-induced head trauma. *J Neurosurg* **124**, 675–686 (2016).
210. Alwis, D. S., Yan, E. B., Morganti-Kossmann, M.-C. & Rajan, R. Sensory cortex underpinnings of traumatic brain injury deficits. *PLoS ONE* **7**, e52169 (2012).
211. Prins, M. L., Alexander, D., Giza, C. C. & Hovda, D. A. Repeated Mild Traumatic Brain Injury: Mechanisms of Cerebral Vulnerability. *Journal of Neurotrauma* **30**, 30–38 (2013).

212. Zhou, Y. & Riccio, D. C. Concussion-induced retrograde amnesia in rats. *Physiology & Behavior* **57**, 1107–1115 (1995).
213. Säljö, A., Bolouri, H., Mayorga, M., Svensson, B. & Hamberger, A. Low-Level Blast Raises Intracranial Pressure and Impairs Cognitive Function in Rats: Prophylaxis with Processed Cereal Feed. *Journal of Neurotrauma* **27**, 383–389 (2010).
214. Wang, H. *et al.* A Compact Blast-Induced Traumatic Brain Injury Model in Mice. *J Neuropathol Exp Neurol* **75**, 183–196 (2016).
215. Johnstone, V. P. A., Yan, E. B., Alwis, D. S. & Rajan, R. Cortical Hypoexcitation Defines Neuronal Responses in the Immediate Aftermath of Traumatic Brain Injury. *PLoS ONE* **8**, e63454 (2013).
216. Chandrasekar, A. *et al.* Parvalbumin Interneurons Shape Neuronal Vulnerability in Blunt TBI. *Cerebral Cortex* **29**, 2701–2715 (2019).
217. Liu, Y. *et al.* Abnormalities in Dynamic Brain Activity Caused by Mild Traumatic Brain Injury Are Partially Rescued by the Cannabinoid Type-2 Receptor Inverse Agonist SMM-189. *eNeuro* **4**, ENEURO.0387-16.2017 (2017).
218. Büchele, F. *et al.* Novel Rat Model of Weight Drop-Induced Closed Diffuse Traumatic Brain Injury Compatible with Electrophysiological Recordings of Vigilance States. *J. Neurotrauma* **33**, 1171–1180 (2016).
219. Bouley, J., Chung, D. Y., Ayata, C., Brown, R. H. & Henninger, N. Cortical Spreading Depression Denotes Concussion Injury. *J. Neurotrauma* **36**, 1008–1017 (2019).
220. Ordek, G. *et al.* Electrophysiological Correlates of Blast-Wave Induced Cerebellar Injury. *Scientific Reports* **8**, (2018).
221. Yu, K. P. *et al.* Effects of Electric Cortical Stimulation (ECS) and Transcranial Direct Current Stimulation (tDCS) on Rats With a Traumatic Brain Injury. *Ann Rehabil Med* **42**, 502–513 (2018).
222. Moskowitz, M. A., Lo, E. H. & Iadecola, C. The science of stroke: mechanisms in search of treatments. *Neuron* **67**, 181–198 (2010).
223. Carmichael, S. T. Brain Excitability in Stroke: The Yin and Yang of Stroke Progression. *Arch Neurol* **69**, 161–167 (2012).
224. Tatemichi, T. K. *et al.* Cognitive impairment after stroke: frequency, patterns, and relationship to functional abilities. *Journal of Neurology, Neurosurgery & Psychiatry* **57**, 202–207 (1994).
225. Patel, M. D., Coshall, C., Rudd, A. G. & Wolfe, C. D. A. Cognitive impairment after stroke: clinical determinants and its associations with long-term stroke outcomes. *J Am Geriatr Soc* **50**, 700–706 (2002).
226. Pollock, A., George, B. S., Fenton, M. & Firkins, L. Top ten research priorities relating to life after stroke. *The Lancet Neurology* **11**, 209 (2012).
227. Jacquin, A. *et al.* Post-Stroke Cognitive Impairment: High Prevalence and Determining Factors in a Cohort of Mild Stroke. *JAD* **40**, 1029–1038 (2014).
228. Grubb, N. R., O'Carroll, R., Cobbe, S. M., Sirel, J. & Fox, K. A. Chronic memory impairment after cardiac arrest outside hospital. *BMJ* **313**, 143–146 (1996).
229. Lim, C., Alexander, M. P., LaFleche, G., Schnyer, D. M. & Verfaellie, M. The neurological and cognitive sequelae of cardiac arrest. *Neurology* **63**, 1774–1778 (2004).
230. Reed, B. R. *et al.* Effects of White Matter Lesions and Lacunes on Cortical Function. *Arch Neurol* **61**, 1545 (2004).
231. Prins, N. D. *et al.* Cerebral White Matter Lesions and the Risk of Dementia. *ARCH NEUROL* **61**, 4 (2004).
232. Lim, C. & ALEXANDER, M. P. Stroke and episodic memory disorders. *Neuropsychologia* **47**, 3045–3058 (2009).
233. Snaphaan, L., Rijpkema, M., Uden, I. v, Fernandez, G. & de Leeuw, F. E. Reduced

medial temporal lobe functionality in stroke patients: a functional magnetic resonance imaging study. *Brain* **132**, 1882–1888 (2009).
234. Schaapsmeerders, P. *et al.* Ipsilateral hippocampal atrophy is associated with long-term memory dysfunction after ischemic stroke in young adults. *Hum. Brain Mapp.* **36**, 2432–2442 (2015).
235. Carrera, E. & Tononi, G. Diaschisis: past, present, future. *Brain* **137**, 2408–2422 (2014).
236. Wathen, C. A., Frizon, L. A., Maiti, T. K., Baker, K. B. & Machado, A. G. Deep brain stimulation of the cerebellum for poststroke motor rehabilitation: from laboratory to clinical trial. *Neurosurgical Focus* **45**, E13 (2018).
237. Corbetta, M., Siegel, J. S. & Shulman, G. L. On the low dimensionality of behavioral deficits and alterations of brain network connectivity after focal injury. *Cortex* **107**, 229–237 (2018).
238. O'Reilly, J. X. *et al.* Causal effect of disconnection lesions on interhemispheric functional connectivity in rhesus monkeys. *Proc. Natl. Acad. Sci. U.S.A.* **110**, 13982–13987 (2013).
239. El Amki, M. *et al.* Experimental modeling of recombinant tissue plasminogen activator effects after ischemic stroke. *Experimental Neurology* **238**, 138–144 (2012).
240. Busch, E., Krüger, K. & Hossmann, K.-A. Improved model of thromboembolic stroke and rt-PA induced reperfusion in the rat. *Brain Research* **778**, 16–24 (1997).
241. Paz, J. T. *et al.* Closed-loop optogenetic control of thalamus as a tool for interrupting seizures after cortical injury. *Nat Neurosci* **16**, 64–70 (2013).
242. Zhang, S., Boyd, J., Delaney, K. & Murphy, T. H. Rapid Reversible Changes in Dendritic Spine Structure In Vivo Gated by the Degree of Ischemia. *J. Neurosci.* **25**, 5333–5338 (2005).
243. KOIZUMI, J. Experimental studies of ischemic brain edema. 1. A new experimental model of cerebral embolism in rats in which recirculation can be introduced in the ischemic area. *Jpn J Stroke* **8**, 1–8 (1986).
244. El Amki, M. *et al.* Hypothalamic, thalamic and hippocampal lesions in the mouse MCAO model: Potential involvement of deep cerebral arteries? *Journal of Neuroscience Methods* **254**, 80–85 (2015).
245. Chen, S. T., Hsu, C. Y., Hogan, E. L., Maricq, H. & Balentine, J. D. A model of focal ischemic stroke in the rat: reproducible extensive cortical infarction. *Stroke* **17**, 738–743 (1986).
246. Leclerc, J. L. *et al.* A Comparison of Pathophysiology in Humans and Rodent Models of Subarachnoid Hemorrhage. *Front. Mol. Neurosci.* **11**, 71 (2018).
247. Gerlai, R. Transient focal cerebral ischemia induces sensorimotor deficits in mice. *Behavioural Brain Research* **108**, 63–71 (2000).
248. Li, W. *et al.* Transient focal cerebral ischemia induces long-term cognitive function deficit in an experimental ischemic stroke model. *Neurobiol Dis* **59**, 18–25 (2013).
249. Brint, S., Jacewicz, M., Kiessling, M., Tanabe, J. & Pulsinelli, W. Focal Brain Ischemia in the Rat: Methods for Reproducible Neocortical Infarction Using Tandem Occlusion of the Distal Middle Cerebral and Ipsilateral Common Carotid Arteries. *J Cereb Blood Flow Metab* **8**, 474–485 (1988).
250. Zhou, L. Y. Y., Wright, T. E. & Clarkson, A. N. Prefrontal cortex stroke induces delayed impairment in spatial memory. *Behav. Brain Res.* **296**, 373–378 (2016).
251. Cordova, C. A., Jackson, D., Langdon, K. D., Hewlett, K. A. & Corbett, D. Impaired executive function following ischemic stroke in the rat medial prefrontal cortex. *Behavioural Brain Research* **258**, 106–111 (2014).
252. Déziel, R. A., Ryan, C. L. & Tasker, R. A. Ischemic lesions localized to the medial

prefrontal cortex produce selective deficits in measures of executive function in rats. *Behavioural Brain Research* **293**, 54–61 (2015).
253. Ejaz, S. *et al.* What is the Optimal Duration of Middle-Cerebral Artery Occlusion Consistently Resulting in Isolated Cortical Selective Neuronal Loss in the Spontaneously Hypertensive Rat? *Front. Neurol.* **6**, (2015).
254. Tamura, A., Graham, D. I., McCulloch, J. & Teasdale, G. M. Focal Cerebral Ischaemia in the Rat: 1. Description of Technique and Early Neuropathological Consequences following Middle Cerebral Artery Occlusion. *J Cereb Blood Flow Metab* **1**, 53–60 (1981).
255. Morris, G. P. *et al.* A Comparative Study of Variables Influencing Ischemic Injury in the Longa and Koizumi Methods of Intraluminal Filament Middle Cerebral Artery Occlusion in Mice. *PLOS ONE* **11**, e0148503 (2016).
256. Buchan, A. M., Xue, D. & Slivka, A. A new model of temporary focal neocortical ischemia in the rat. *Stroke* **23**, 273–279 (1992).
257. Sicard, K. M., Henninger, N., Fisher, M., Duong, T. Q. & Ferris, C. F. Long-Term Changes of Functional MRI–Based Brain Function, Behavioral Status, and Histopathology After Transient Focal Cerebral Ischemia in Rats. *Stroke* **37**, 2593–2600 (2006).
258. Rabiller, G. Contribution of hippocampal diaschisis to the memory deficits associated with focal cerebral ischemia in the rat : converging behavioral, electrophysiological and functional evidence. (Université de Bordeaux, 2015).
259. Tominaga, T. & Ohnishi, S. T. Interrelationship of brain edema, motor deficits, and memory impairment in rats exposed to focal ischemia. *Stroke* **20**, 513–518 (1989).
260. Roof, R. L., Schielke, G. P., Ren, X. & Hall, E. D. A comparison of long-term functional outcome after 2 middle cerebral artery occlusion models in rats. *Stroke* **32**, 2648–2657 (2001).
261. Wang, Y. *et al.* A Comprehensive Analysis of Gait Impairment after Experimental Stroke and the Therapeutic Effect of Environmental Enrichment in Rats. *J Cereb Blood Flow Metab* **28**, 1936–1950 (2008).
262. Matsumori, Y. *et al.* Enriched environment and spatial learning enhance hippocampal neurogenesis and salvages ischemic penumbra after focal cerebral ischemia. *Neurobiology of Disease* **22**, 187–198 (2006).
263. Wayman, C. *et al.* Performing Permanent Distal Middle Cerebral with Common Carotid Artery Occlusion in Aged Rats to Study Cortical Ischemia with Sustained Disability. *J Vis Exp* (2016) doi:10.3791/53106.
264. Freret, T. *et al.* Long-term functional outcome following transient middle cerebral artery occlusion in the rat: Correlation between brain damage and behavioral impairment. *Behavioral Neuroscience* **120**, 1285–1298 (2006).
265. Kataoka, K., Hayakawa, T., Kuroda, R., Yuguchi, T. & Yamada, K. Cholinergic deafferentation after focal cerebral infarct in rats. *Stroke* **22**, 1291–1296 (1991).
266. Baumgartner, P., El Amki, M., Bracko, O., Luft, A. R. & Wegener, S. Sensorimotor stroke alters hippocampo-thalamic network activity. *Sci Rep* 1–11 (2018) doi:10.1038/s41598-018-34002-9.
267. Kataoka, K. *et al.* Neuronal network disturbance after focal ischemia in rats. *Stroke* **20**, 1226–1235 (1989).
268. Zhang, J., Zhang, Y., Xing, S., Liang, Z. & Zeng, J. Secondary Neurodegeneration in Remote Regions After Focal Cerebral Infarction: A New Target for Stroke Management? *Stroke* **43**, 1700–1705 (2012).
269. van Groen, T., Puurunen, K., Mäki, H.-M., Sivenius, J. & Jolkkonen, J. Transformation of Diffuse β-Amyloid Precursor Protein and β-Amyloid Deposits to Plaques in the Thalamus After Transient Occlusion of the Middle Cerebral Artery in Rats. *Stroke* **36**, 1551–1556 (2005).

270. Markgraf, C. G. *et al.* Sensorimotor and cognitive consequences of middle cerebral artery occlusion in rats. *Brain Research* **575**, 238–246 (1992).
271. Yonemori, F., Yamaguchi, T., Yamada, H. & Tamura, A. Spatial Cognitive Performance after Chronic Focal Cerebral Ischemia in Rats. *Journal of Cerebral Blood Flow & Metabolism* **19**, 483–494 (1999).
272. Bingham, D., Martin, S. J., Macrae, I. M. & Carswell, H. V. O. Watermaze Performance after Middle Cerebral Artery Occlusion in the Rat: The Role of Sensorimotor versus Memory Impairments. *J Cereb Blood Flow Metab* **32**, 989–999 (2012).
273. Wahl, F., Allix, M., Plotkine, M. & Boulu, R. G. Neurological and behavioral outcomes of focal cerebral ischemia in rats. *Stroke* **23**, 267–272 (1992).
274. Freret, T. *et al.* Behavioral deficits after distal focal cerebral ischemia in mice: Usefulness of adhesive removal test. *Behavioral Neuroscience* **123**, 224–230 (2009).
275. Yonemori, F., Yamada, H., Yamaguchi, T., Uemura, A. & Tamura, A. Spatial Memory Disturbance after Focal Cerebral Ischemia in Rats. *Journal of Cerebral Blood Flow & Metabolism* **16**, 973–980 (1996).
276. Hirakawa, M., Tamura, A., Nagashima, H., Nakayama, H. & Sano, K. Disturbance of retention of memory after focal cerebral ischemia in rats. *Stroke* **25**, 2471–2475 (1994).
277. Okada, M. *et al.* Long-Term Spatial Cognitive Impairment after Middle Cerebral Artery Occlusion in Rats: No Involvement of the Hippocampus. *Journal of Cerebral Blood Flow & Metabolism* **15**, 1012–1021 (1995).
278. Houlton, J., Zhou, L. Y. Y., Barwick, D., Gowing, E. K. & Clarkson, A. N. Stroke Induces a BDNF-Dependent Improvement in Cognitive Flexibility in Aged Mice. *Neural Plasticity* **2019**, 1–14 (2019).
279. Bederson, J. B. *et al.* Rat middle cerebral artery occlusion: evaluation of the model and development of a neurologic examination. *Stroke* **17**, 472–476 (1986).
280. Bouët, V. *et al.* Sensorimotor and cognitive deficits after transient middle cerebral artery occlusion in the mouse. *Experimental Neurology* **203**, 555–567 (2007).
281. Yonemori, F., Yamaguchi, T., Yamada, H. & Tamura, A. Evaluation of a motor deficit after chronic focal cerebral ischemia in rats. *J. Cereb. Blood Flow Metab.* **18**, 1099–1106 (1998).
282. Iadecola, C., Zhang, F., Casey, R., Nagayama, M. & Ross, M. E. Delayed Reduction of Ischemic Brain Injury and Neurological Deficits in Mice Lacking the Inducible Nitric Oxide Synthase Gene. *J. Neurosci.* **17**, 9157–9164 (1997).
283. Bouet, V. *et al.* The adhesive removal test: a sensitive method to assess sensorimotor deficits in mice. *Nat Protoc* **4**, 1560–1564 (2009).
284. Gonzalez, C. L. R. & Kolb, B. A comparison of different models of stroke on behaviour and brain morphology. *Eur J Neurosci* **18**, 1950–1962 (2003).
285. Sanchez-Bezanilla, S., TeBay, C., Nilsson, M., Walker, F. R. & Ong, L. K. Visual discrimination impairment after experimental stroke is associated with disturbances in the polarization of the astrocytic aquaporin-4 and increased accumulation of neurotoxic proteins. *Experimental Neurology* **318**, 232–243 (2019).
286. Mohammadzadeh, L. *et al.* Measuring the Frequency-Specific Functional Connectivity Using Wavelet Coherence Analysis in Stroke Rats Based on Intrinsic Signals. *Scientific Reports* **10**, 9429 (2020).
287. Robinson, R. Differential behavioral and biochemical effects of right and left hemispheric cerebral infarction in the rat. *Science* **205**, 707 (1979).
288. Winter, B. *et al.* Anxious and Hyperactive Phenotype Following Brief Ischemic Episodes in Mice. *Biological Psychiatry* **57**, 1166–1175 (2005).
289. Cheng, Y. *et al.* 17 β -Estradiol attenuates poststroke depression and increases neurogenesis in female ovariectomized rats. *Biomed Res Int* **2013**, 392434 (2013).

290. Boyko, M. *et al.* The influence of aging on poststroke depression using a rat model via middle cerebral artery occlusion. *Cogn Affect Behav Neurosci* **13**, 847–859 (2013).
291. Zhang, G. *et al.* Combined use of spatial restraint stress and middle cerebral artery occlusion is a novel model of post-stroke depression in mice. *Sci Rep* **5**, 16751 (2015).
292. Kronenberg, G., Gertz, K., Heinz, A. & Endres, M. Of mice and men: modelling post-stroke depression experimentally: Modelling post-stroke depression experimentally. *Br J Pharmacol* **171**, 4673–4689 (2014).
293. Vahid-Ansari, F., Lagace, D. C. & Albert, P. R. Persistent post-stroke depression in mice following unilateral medial prefrontal cortical stroke. *Transl Psychiatry* **6**, e863–e863 (2016).
294. Hagemann, G., Redecker, C., Neumann-Haefelin, T., Freund, H.-J. & Witte, O. W. Increased long-term potentiation in the surround of experimentally induced focal cortical infarction. *Ann Neurol.* **44**, 255–258 (1998).
295. Neumann-Haefelin, T. & Witte, O. W. Periinfarct and Remote Excitability Changes after Transient Middle Cerebral Artery Occlusion. *J Cereb Blood Flow Metab* **20**, 45–52 (2000).
296. Neumann-Haefelin, T., Hagemann, G. & Witte, O. W. Cellular correlates of neuronal hyperexcitability in the vicinity of photochemically induced cortical infarcts in rats in vitro. *Neuroscience Letters* **193**, 101–104 (1995).
297. Buchkremer-Ratzmann, I. & Witte, O. W. Extended brain disinhibition following small photothrombotic lesions in rat frontal cortex. *Neuroreport* **8**, 519–522 (1997).
298. van Meer, M. P. A. *et al.* Extent of Bilateral Neuronal Network Reorganization and Functional Recovery in Relation to Stroke Severity. *J Neurosci* **32**, 4495–4507 (2012).
299. Green, C. *et al.* Sensorimotor Functional and Structural Networks after Intracerebral Stem Cell Grafts in the Ischemic Mouse Brain. *J. Neurosci.* **38**, 1648–1661 (2018).
300. Bauer, A. Q. *et al.* Optical imaging of disrupted functional connectivity following ischemic stroke in mice. *Neuroimage* **99**, 388–401 (2014).
301. Shim, W. H., Suh, J.-Y., Kim, J. K., Jeong, J. & Kim, Y. R. Enhanced Thalamic Functional Connectivity with No fMRI Responses to Affected Forelimb Stimulation in Stroke-Recovered Rats. *Front Neural Circuits* **10**, 113 (2016).
302. Moyanova, S. G. & Dijkhuizen, R. M. Present status and future challenges of electroencephalography- and magnetic resonance imaging-based monitoring in preclinical models of focal cerebral ischemia. *Brain Research Bulletin* **102**, 22–36 (2014).
303. Zhang, S., Ke, Z., Li, L., Yip, S. & Tong, K. EEG patterns from acute to chronic stroke phases in focal cerebral ischemic rats: correlations with functional recovery. *Physiological Measurement* **34**, 423–435 (2013).
304. Hartings, J. A., Williams, A. J. & Tortella, F. C. Occurrence of nonconvulsive seizures, periodic epileptiform discharges, and intermittent rhythmic delta activity in rat focal ischemia. *Experimental Neurology* **179**, 139–149 (2003).
305. Bentes, C. *et al.* Quantitative EEG and functional outcome following acute ischemic stroke. *Clinical Neurophysiology* **129**, 1680–1687 (2018).
306. Gloor, P., Ball, G. & Schaul, N. Brain lesions that produce delta waves in the EEG. *Neurology* **27**, 326–326 (1977).
307. Lu, X.-C. M., Williams, A. J. & Tortella, F. C. Quantitative electroencephalography spectral analysis and topographic mapping in a rat model of middle cerebral artery occlusion. *Neuropathology and Applied Neurobiology* **27**, 481–495 (2001).
308. Baumann, C. R. *et al.* Sleep EEG Changes After Middle Cerebral Artery Infarcts in Mice: Different Effects of Striatal and Cortical Lesions. *Sleep* **29**, 1339–1344 (2006).
309. Mies, G., Iijima, T. & Hossmann, K. A. Correlation between peri-infarct DC shifts and ischaemic neuronal damage in rat. *Neuroreport* **4**, 709–711 (1993).

310. Sopala, M., Frankiewicz, T., Parsons, C. & Danysz, W. Middle cerebral artery occlusion produces secondary, remote impairment in hippocampal plasticity of rats - involvement of N-methyl-D-aspartate receptors? *Neurosci. Lett.* **281**, 143–146 (2000).
311. Rabiller, G., He, J.-W., Nishijima, Y., Wong, A. & Liu, J. Perturbation of Brain Oscillations after Ischemic Stroke: A Potential Biomarker for Post-Stroke Function and Therapy. *International Journal of Molecular Sciences* **16**, 25605–25640 (2015).
312. Kharlamov, E. A., Jukkola, P. I., Schmitt, K. L. & Kelly, K. M. Electrobehavioral characteristics of epileptic rats following photothrombotic brain infarction. *Epilepsy Research* **56**, 185–203 (2003).
313. Karhunen, H. *et al.* Epileptogenesis after cortical photothrombotic brain lesion in rats. *Neuroscience* **148**, 314–324 (2007).
314. Karhunen, H. *et al.* Long-term functional consequences of transient occlusion of the middle cerebral artery in rats: a 1-year follow-up of the development of epileptogenesis and memory impairment in relation to sensorimotor deficits. *Epilepsy Res* **54**, 1–10 (2003).
315. Kelly, K. M. Animal Modeling of Poststroke Seizures and Epilepsy: 5-Year Update. *Epilepsy Currents* **7**, 159–162 (2007).
316. García, I. *et al.* Periodic Lateralized Epileptiform Discharges. *J Clin Neurophysiol* **19**, 6 (2002).
317. Liang, S. *et al.* Abnormal Metabolic Connectivity in Rats at the Acute Stage of Ischemic Stroke. *Neurosci. Bull.* **34**, 715–724 (2018).
318. Centonze, D. *et al.* Synaptic plasticity during recovery from permanent occlusion of the middle cerebral artery. *Neurobiology of Disease* **27**, 44–53 (2007).
319. Adkins-Muir, D. L. & Jones, T. A. Cortical electrical stimulation combined with rehabilitative training: Enhanced functional recovery and dendritic plasticity following focal cortical ischemia in rats. *Neurological Research* **25**, 780–788 (2003).
320. Machado, A. G., Baker, K. B., Schuster, D., Butler, R. S. & Rezai, A. Chronic electrical stimulation of the contralesional lateral cerebellar nucleus enhances recovery of motor function after cerebral ischemia in rats. *Brain Research* **1280**, 107–116 (2009).
321. Shah, A. M. *et al.* Optogenetic neuronal stimulation of the lateral cerebellar nucleus promotes persistent functional recovery after stroke. *Sci Rep* **7**, 46612 (2017).
322. Farkas, E., Luiten, P. G. M. & Bari, F. Permanent, bilateral common carotid artery occlusion in the rat: A model for chronic cerebral hypoperfusion-related neurodegenerative diseases. *Brain Research Reviews* **54**, 162–180 (2007).
323. Cohan, C. H. *et al.* Effect of Cardiac Arrest on Cognitive Impairment and Hippocampal Plasticity in Middle-Aged Rats. *PLoS ONE* **10**, (2015).
324. Pulsinelli, W. A., Brierley, J. B. & Plum, F. Temporal profile of neuronal damage in a model of transient forebrain ischemia. *Ann. Neurol.* **11**, 491–498 (1982).
325. Sarti, C., Pantoni, L., Bartolini, L. & Inzitari, D. Persistent impairment of gait performances and working memory after bilateral common carotid artery occlusion in the adult Wistar rat. *Behavioural Brain Research* **136**, 13–20 (2002).
326. Northington, F. J. Brief Update on Animal Models of Hypoxic-Ischemic Encephalopathy and Neonatal Stroke. *ILAR Journal* **47**, 32–38 (2006).
327. Rice, J. E., Vannucci, R. C. & Brierley, J. B. The influence of immaturity on hypoxic-ischemic brain damage in the rat. *Ann Neurol.* **9**, 131–141 (1981).
328. Smith, M.-L., Auer, R. N. & Siesjö, B. K. The density and distribution of ischemic brain injury in the rat following 2-10 min of forebrain ischemia. *Acta Neuropathol* **64**, 319–332 (1984).
329. García-Chávez, D. *et al.* Long-term evaluation of cytoarchitectonic characteristics of prefrontal cortex pyramidal neurons, following global cerebral ischemia and neuroprotective melatonin treatment, in rats. *Neuroscience Letters* 5 (2008).

330. Kirino, T., Tamura, A. & Sano, K. Delayed neuronal death in the rat hippocampus following transient forebrain ischemia. *Acta Neuropathol* **64**, 139–147 (1984).
331. Nikonenko, A. G., Radenovic, L., Andjus, P. R. & Skibo, G. G. Structural Features of Ischemic Damage in the Hippocampus. *The Anatomical Record: Advances in Integrative Anatomy and Evolutionary Biology* **292**, 1914–1921 (2009).
332. Kirino, T. Delayed neuronal death. *Neuropathology* **20 Suppl**, S95-97 (2000).
333. Böttiger, B. W., Schmitz, B., Wiessner, C., Vogel, P. & Hossmann, K. A. Neuronal stress response and neuronal cell damage after cardiocirculatory arrest in rats. *J. Cereb. Blood Flow Metab.* **18**, 1077–1087 (1998).
334. Petito, C. K., Feldmann, E., Pulsinelli, W. A. & Plum, F. Delayed hippocampal damage in humans following cardiorespiratory arrest. *Neurology* **37**, 1281–1286 (1987).
335. Hsu, M. & Buzsáki, G. Vulnerability of mossy fiber targets in the rat hippocampus to forebrain ischemia. *J. Neurosci.* **13**, 3964–3979 (1993).
336. Freund, T. F., Buzsáki, G., Leon, A. & Somogyi, P. Hippocampal cell death following ischemia: Effects of brain temperature and anesthesia. *Experimental Neurology* **108**, 251–260 (1990).
337. Johansen, F. F., Zimmer, J. & Diemer, N. H. Early loss of somatostatin neurons in dentate hilus after cerebral ischemia in the rat precedes CA-1 pyramidal cell loss. *Acta Neuropathol* **73**, 110–114 (1987).
338. Bering, R., Draguhn, A., Diemer, N. H. & Johansen, F. F. Ischemia changes the coexpression of somatostatin and neuropeptide Y in hippocampal interneurons. *Exp Brain Res* **115**, 423–429 (1997).
339. Hattori, Y. *et al.* Gradual Carotid Artery Stenosis in Mice Closely Replicates Hypoperfusive Vascular Dementia in Humans. *J Am Heart Assoc* **5**, (2016).
340. Shibata, M. *et al.* Selective Impairment of Working Memory in a Mouse Model of Chronic Cerebral Hypoperfusion. *Stroke* **38**, 2826–2832 (2007).
341. Terashima, T. *et al.* Consistent injury in the striatum of C57BL/6 mice after transient bilateral common carotid artery occlusion. *Neurosurgery* **43**, 900–907; discussion 907-908 (1998).
342. Yoshioka, H. *et al.* Consistent Injury to Medium Spiny Neurons and White Matter in the Mouse Striatum after Prolonged Transient Global Cerebral Ischemia. *J Neurotrauma* **28**, 649–660 (2011).
343. Diemer, N. H. & Siemkowicz, E. REGIONAL NEURONE DAMAGE AFTER CEREBRAL ISCHAEMIA IN THE NORMO- AND HYPOGLYCAEMIC RAT. *Neuropathol Appl Neurobiol* **7**, 217–227 (1981).
344. Smith, M. L., Kalimo, H., Warner, D. S. & Siesjo, B. K. Morphological lesions in the brain preceding the development of postischemic seizures. *Acta Neuropathol* **76**, 253–264 (1988).
345. Stone, B. S. *et al.* Delayed neural network degeneration after neonatal hypoxia-ischemia. *Annals of Neurology* **64**, 535–546 (2008).
346. Stevens, W. D., Fortin, T. & Pappas, B. A. Retinal and Optic Nerve Degeneration After Chronic Carotid Ligation: Time Course and Role of Light Exposure. *Stroke* **33**, 1107–1112 (2002).
347. Yamamoto, H., Schmidt-Kastner, R., Hamasaki, D. I., Yamamoto, H. & Parel, J.-M. Complex neurodegeneration in retina following moderate ischemia induced by bilateral common carotid artery occlusion in Wistar rats. *Experimental Eye Research* **82**, 767–779 (2006).
348. Levine, S. & Payan, H. Effects of ischemia and other procedures on the brain and retina of the gerbil (Meriones unguiculatus). *Experimental Neurology* **16**, 255–262 (1966).
349. Lim, S. H. & Lee, J. Hot Water Extract of Wheat Bran Attenuates White Matter Injury

in a Rat Model of Vascular Dementia. *JFN* **19**, 145–155 (2014).
350. Ohta, H., Nishikawa, H., Kimura, H., Anayama, H. & Miyamoto, M. Chronic cerebral hypoperfusion by permanent internal carotid ligation produces learning impairment without brain damage in rats. *Neuroscience* **79**, 1039–1050 (1997).
351. Xu, X., Li, Z., Yang, Z. & Zhang, T. Decrease of synaptic plasticity associated with alteration of information flow in a rat model of vascular dementia. *Neuroscience* **206**, 136–143 (2012).
352. Xu, X., Liu, C., Li, Z. & Zhang, T. Effects of Hydrogen Sulfide on Modulation of Theta–Gamma Coupling in Hippocampus in Vascular Dementia Rats. *Brain Topography* **28**, 879–894 (2015).
353. Sun, M.-K., Hongpaisan, J. & Alkon, D. L. Postischemic PKC activation rescues retrograde and anterograde long-term memory. *Proceedings of the National Academy of Sciences* **106**, 14676–14680 (2009).
354. Coltman, R. *et al.* Selective white matter pathology induces a specific impairment in spatial working memory. *Neurobiology of Aging* **32**, 2324.e7-2324.e12 (2011).
355. Nunn, J. A. *et al.* Global ischaemia: Hippocampal pathology and spatial deficits in the water maze. *Behavioural Brain Research* **62**, 41–54 (1994).
356. Gondard, E. *et al.* Deep Brain Stimulation rescues memory and synaptic activity in a rat model of global ischemia. *J. Neuroscience* 1222–18 (2019) doi:10.1523/JNEUROSCI.1222-18.2019.
357. Hartman, R. E., Lee, J. M., Zipfel, G. J. & Wozniak, D. F. Characterizing learning deficits and hippocampal neuron loss following transient global cerebral ischemia in rats. *Brain Research* **1043**, 48–56 (2005).
358. Mumby, D. G. *et al.* Ischemia-induced object-recognition deficits in rats are attenuated by hippocampal ablation before or soon after ischemia. *Behav Neurosci* **110**, 266–281 (1996).
359. Karasawa, Y., Araki, H. & Otomo, S. Changes in locomotor activity and passive avoidance task performance induced by cerebral ischemia in Mongolian gerbils. *Stroke* **25**, 645–650 (1994).
360. Pappas, B. A., de la Torre, J. C., Davidson, C. M., Keyes, M. T. & Fortin, T. Chronic reduction of cerebral blood flow in the adult rat: late-emerging CA1 cell loss and memory dysfunction. *Brain Res.* **708**, 50–58 (1996).
361. Volpe, B. T., Davis, H. P., Towle, A. & Dunlap, W. P. Loss of hippocampal CA1 pyramidal neurons correlates with memory impairment in rats with ischemic or neurotoxin lesions. *Behav Neurosci* **106**, 457–464 (1992).
362. Wu, C. Y. C. *et al.* Utilizing the Modified T-Maze to Assess Functional Memory Outcomes After Cardiac Arrest. *JoVE* 56694 (2018) doi:10.3791/56694.
363. Kiprianova, I., Sandkühler, J., Schwab, S., Hoyer, S. & Spranger, M. Brain-derived neurotrophic factor improves long-term potentiation and cognitive functions after transient forebrain ischemia in the rat. *Exp. Neurol.* **159**, 511–519 (1999).
364. Sopala, M. & Danysz, W. Chronic cerebral hypoperfusion in the rat enhances age-related deficits in spatial memory. *Journal of Neural Transmission* **108**, 1445–1456 (2001).
365. Davidson, C. M., Pappas, B. A., Stevens, W. D., Fortin, T. & Bennett, S. A. L. Chronic cerebral hypoperfusion: loss of pupillary reflex, visual impairment and retinal neurodegeneration. *Brain Research* **859**, 96–103 (2000).
366. Yan, B. *et al.* Quetiapine attenuates the depressive and anxiolytic-like behavioural changes induced by global cerebral ischemia in mice. *Behavioural Brain Research* **182**, 36–41 (2007).
367. Milot, M. R. & Plamondon, H. Time-dependent effects of global cerebral ischemia on anxiety, locomotion, and habituation in rats. *Behavioural Brain Research* **200**, 173–180 (2009).

368. Liu, S., Han, S., Dai, Q., Li, S. & Li, J. BICAO-induced ischaemia caused depressive-like behaviours and caspase-8/-9-dependent brain regional neural cell apoptosis in mice. *Stroke Vasc Neurol* **3**, 1–8 (2018).
369. Fortuna, S. *et al.* Transient global brain hypoxia-ischemia in adult rats: Neuronal damage, glial proliferation, and alterations in inositol phospholipid hydrolysis. *Neurochemistry International* **31**, 563–569 (1997).
370. Mariucci, G. *et al.* EEG Power Spectra Changes and Forebrain Ischemia in Rats. *Can. j. neurol. sci.* **30**, 54–60 (2003).
371. Monmaur, P., Thomson, M. A. & M'Harzi, M. Temporal changes in hippocampal theta activity following twenty minutes of forebrain ischemia in the chronic rat. *Brain Res.* **378**, 262–273 (1986).
372. Buzsaki, G., Freund, T. F., Bayardo, F. & Somogyi, P. Ischemia-induced changes in the electrical activity of the hippocampus. *Experimental Brain Research* **78**, (1989).
373. Brockmann, M. D., Kukovic, M., Schönfeld, M., Sedlacik, J. & Hanganu-Opatz, I. L. Hypoxia-Ischemia Disrupts Directed Interactions within Neonatal Prefrontal-Hippocampal Networks. *PLoS ONE* **8**, e83074 (2013).
374. Middleton, J. W. *et al.* Long-Term Deficits in Cortical Circuit Function after Asphyxial Cardiac Arrest and Resuscitation in Developing Rats. *eNeuro* **4**, (2017).
375. Strata, F. *et al.* Perinatal Asphyxia Affects Rat Auditory Processing: Implications for Auditory Perceptual Impairments in Neurodevelopmental Disorders. *PLoS One* **5**, (2010).
376. Suzuki, R., Yamaguchi, T., Li, C.-L. & Klatzo, I. The effects of 5-minute ischemia in Mongolian gerbils: II. Changes of spontaneous neuronal activity in cerebral cortex and CA1 sector of hippocampus. *Acta Neuropathol* **60**, 217–222 (1983).
377. Henrich-Noack, P., Gorkin, A. G. & Reymann, K. G. Predictive value of changes in electroencephalogram and excitatory postsynaptic field potential for CA1 damage after global ischaemia in rats. *Exp Brain Res* **181**, 79–86 (2007).
378. Congar, P., Gaïarsa, J.-L., Popovici, T., Ben-Ari, Y. & Crépel, V. Permanent Reduction of Seizure Threshold in Post-Ischemic CA3 Pyramidal Neurons. *Journal of Neurophysiology* **83**, 2040–2046 (2000).
379. Crépel, V., Hammond, C., Chinestra, P., Diabira, D. & Ben-Ari, Y. A selective LTP of NMDA receptor-mediated currents induced by anoxia in CA1 hippocampal neurons. *J. Neurophysiol.* **70**, 2045–2055 (1993).
380. Hsu, K.-S. & Huang, C.-C. Characterization of the anoxia-induced long-term synaptic potentiation in area CA1 of the rat hippocampus. *Br J Pharmacol* **122**, 671–681 (1997).
381. Miyazaki, S. *et al.* Post-ischemic potentiation of Schaffer collateral/CA1 pyramidal cell responses of the rat hippocampus in vivo: involvement of N-methyl-D-aspartate receptors. *Brain Res.* **611**, 155–159 (1993).
382. Gao, T. M., Pulsinelli, W. A. & Xu, Z. C. Prolonged enhancement and depression of synaptic transmission in CA1 pyramidal neurons induced by transient forebrain ischemia in vivo. *Neuroscience* **87**, 371–383 (1998).
383. Orfila, J. E. *et al.* Cardiac Arrest Induces Ischemic Long-Term Potentiation of Hippocampal CA1 Neurons That Occludes Physiological Long-Term Potentiation. *Neural Plasticity* **2018**, 1–9 (2018).
384. Li, Z., Wang, Y., Xie, Y., Yang, Z. & Zhang, T. Protective Effects of Exogenous Hydrogen Sulfide on Neurons of Hippocampus in a Rat Model of Brain Ischemia. *Neurochem Res* **36**, 1840–1849 (2011).
385. Xu, X., Zheng, C. & Zhang, T. Reduction in LFP cross-frequency coupling between theta and gamma rhythms associated with impaired STP and LTP in a rat model of brain ischemia. *Frontiers in Computational Neuroscience* **7**, (2013).
386. Stein, E. S. *et al.* Thrombin induces ischemic LTP (iLTP): implications for synaptic

plasticity in the acute phase of ischemic stroke. *Sci Rep* **5**, (2015).
387. Wang, S., Kee, N., Preston, E. & Wojtowicz, J. M. Electrophysiological correlates of neural plasticity compensating for ischemia-induced damage in the hippocampus. *Exp Brain Res* **165**, 250–260 (2005).
388. Senova, S., Chaillet, A. & Lozano, A. M. Fornical Closed-Loop Stimulation for Alzheimer's Disease. *Trends in Neurosciences* 1–11 (2018) doi:10.1016/j.tins.2018.03.015.
389. Escobar, I., Xu, J., Jackson, C. W. & Perez-Pinzon, M. A. Altered Neural Networks in the Papez Circuit: Implications for Cognitive Dysfunction after Cerebral Ischemia. *J Alzheimers Dis* **67**, 425–446 (2019).
390. Koh, M. T., Haberman, R. P., Foti, S., McCown, T. J. & Gallagher, M. Treatment Strategies Targeting Excess Hippocampal Activity Benefit Aged Rats with Cognitive Impairment. *Neuropsychopharmacology* **35**, 1016–1025 (2010).
391. Ellwardt, E. *et al.* Maladaptive cortical hyperactivity upon recovery from experimental autoimmune encephalomyelitis. *Nat Neurosci* **21**, 1392–1403 (2018).
392. Mormann, F. *et al.* Phase/amplitude reset and theta-gamma interaction in the human medial temporal lobe during a continuous word recognition memory task. *Hippocampus* **15**, 890–900 (2005).
393. Kitchigina, V. F. Alterations of Coherent Theta and Gamma Network Oscillations as an Early Biomarker of Temporal Lobe Epilepsy and Alzheimer's Disease. *Frontiers in Integrative Neuroscience* **12**, 1051–15 (2018).
394. Canals, S., Beyerlein, M., Merkle, H. & Logothetis, N. K. Functional MRI Evidence for LTP-Induced Neural Network Reorganization. *Current Biology* **19**, 398–403 (2009).
395. Maia, P. D., Raj, A. & Kutz, J. N. Slow-gamma frequencies are optimally guarded against effects of neurodegenerative diseases and traumatic brain injuries. *J Comput Neurosci* **47**, 1–16 (2019).
396. Bikbaev, A. & Manahan-Vaughan, D. Relationship of Hippocampal Theta and Gamma Oscillations to Potentiation of Synaptic Transmission. *Front Neurosci* **2**, 56–63 (2008).
397. Hölscher, C., Anwyl, R. & Rowan, M. J. Stimulation on the positive phase of hippocampal theta rhythm induces long-term potentiation that can Be depotentiated by stimulation on the negative phase in area CA1 in vivo. *J. Neuroscience* **17**, 6470–6477 (1997).
398. Gondard, E. *et al.* Rapid modulation of protein expression in the rat hippocampus following deep brain stimulation of the fornix. *Brain Stimulation* 1–30 (2015) doi:10.1016/j.brs.2015.07.044.
399. Broggini, A. C. S., Esteves, I. M., Romcy-Pereira, R. N., Leite, J. P. & Leão, R. N. Pre-ictal increase in theta synchrony between the hippocampus and prefrontal cortex in a rat model of temporal lobe epilepsy. *Experimental Neurology* **279**, 232–242 (2016).
400. Ibrahim, G. M. *et al.* Dynamic modulation of epileptic high frequency oscillations by the phase of slower cortical rhythms. *Exp. Neurol.* **251**, 30–38 (2014).
401. Engelhardt, E. & Gomes, M. da M. Shock, diaschisis and von Monakow. *Arq. Neuro-Psiquiatr.* **71**, 487–489 (2013).
402. Tennant, K. A., Taylor, S. L., White, E. R. & Brown, C. E. Optogenetic rewiring of thalamocortical circuits to restore function in the stroke injured brain. *Nat Commun* **8**, 15879 (2017).
403. Bueno-Junior, L. S. & Leite, J. P. Input Convergence, Synaptic Plasticity and Functional Coupling Across Hippocampal-Prefrontal-Thalamic Circuits. *Frontiers in Neural Circuits* **12**, (2018).
404. de Lavilléon, G., Lacroix, M. M., Rondi-Reig, L. & Benchenane, K. Explicit memory creation during sleep demonstrates a causal role of place cells in navigation. *Nat Neurosci* **18**,

493–495 (2015).
405. Ognjanovski, N., Broussard, C., Zochowski, M. & Aton, S. J. Hippocampal Network Oscillations Rescue Memory Consolidation Deficits Caused by Sleep Loss. *Cereb Cortex* **28**, 3711–3723 (2018).
406. Gao, X. *et al.* Selective Death of Newborn Neurons in Hippocampal Dentate Gyrus Following Moderate Experimental Traumatic Brain Injury. *J Neurosci Res* **86**, 2258–2270 (2008).
407. Ibrahim, S. *et al.* Traumatic Brain Injury Causes Aberrant Migration of Adult-Born Neurons in the Hippocampus. *Scientific Reports* **6**, (2016).
408. Long, J. A. *et al.* Multiparametric and Longitudinal MRI Characterization of Mild Traumatic Brain Injury in Rats. *J Neurotrauma* **32**, 598–607 (2015).
409. Wright, D. K. *et al.* Changes in Apparent Fiber Density and Track-Weighted Imaging Metrics in White Matter following Experimental Traumatic Brain Injury. *J. Neurotrauma* **34**, 2109–2118 (2017).
410. Chen, Y., Constantini, S., Trembovler, V., Weinstock, M. & Shohami, E. An Experimental Model of Closed Head Injury in Mice: Pathophysiology, Histopathology, and Cognitive Deficits. *Journal of Neurotrauma* **13**, 557–568 (1996).
411. Shapira, Y., Setton, D., Artru, A. A. & Shohami, E. Blood-brain barrier permeability, cerebral edema, and neurologic function after closed head injury in rats. *Anesth Analg* **77**, 141–148 (1993).
412. Pluta, R., Januszewski, S., Jabłoński, M. & Ułamek, M. Factors in creepy delayed neuronal death in hippocampus following brain ischemia-reperfusion injury with long-term survival. *Acta Neurochir. Suppl.* **106**, 37–41 (2010).
413. Johnstone, V. P. A., Shultz, S. R., Yan, E. B., O'Brien, T. J. & Rajan, R. The acute phase of mild traumatic brain injury is characterized by a distance-dependent neuronal hypoactivity. *J. Neurotrauma* **31**, 1881–1895 (2014).
414. Reeves, T. M., Kao, C.-Q., Phillips, L. L., Bullock, M. R. & Povlishock, J. T. Presynaptic excitability changes following traumatic brain injury in the rat. *Journal of Neuroscience Research* **60**, 370–379 (2000).
415. Allitt, B. J., Iva, P., Yan, E. B. & Rajan, R. Hypo-excitation across all cortical laminae defines intermediate stages of cortical neuronal dysfunction in diffuse traumatic brain injury. *Neuroscience* **334**, 290–308 (2016).

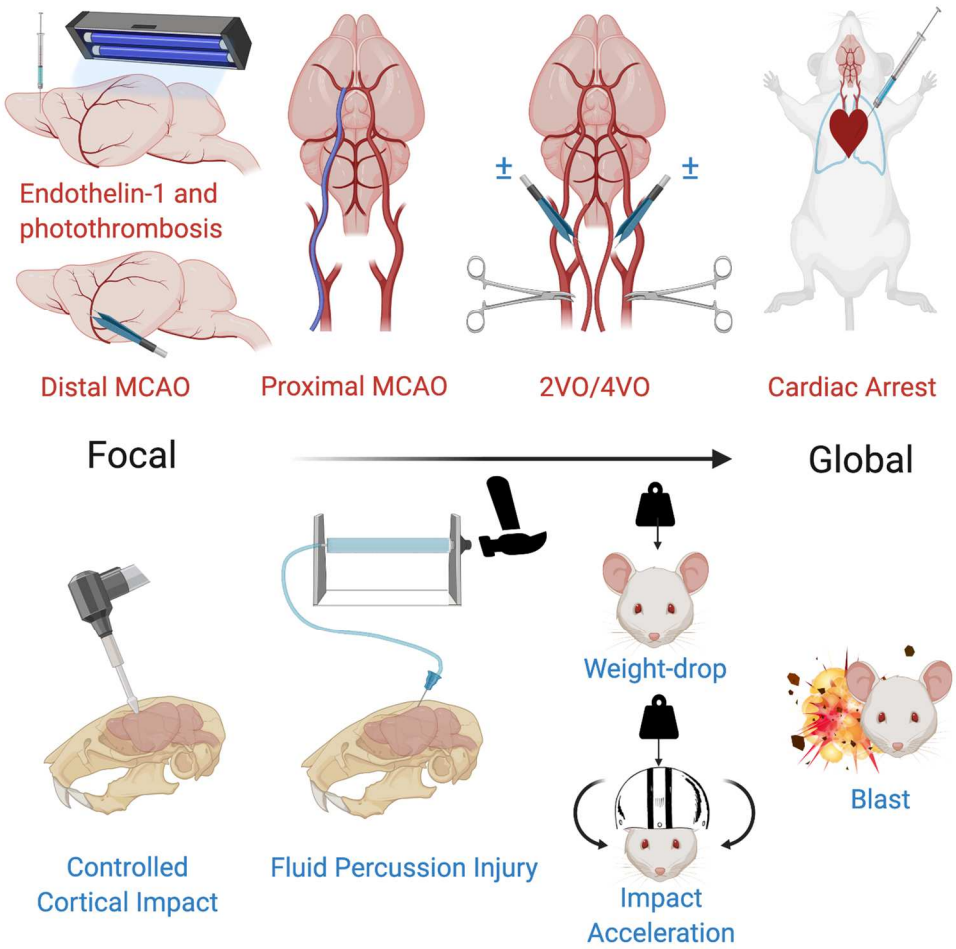

Figure 1 : Rodent models of TBI and ischemia

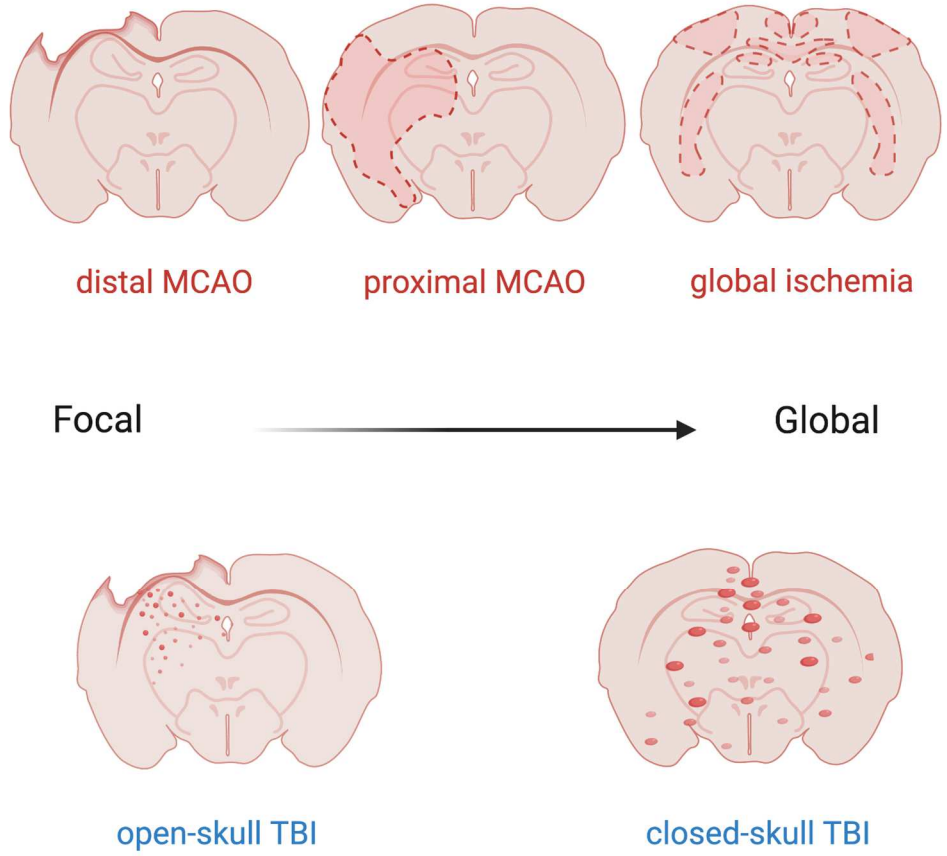

Figure 2 : Different patterns of structural damage across rodent models of traumatic brain injury or brain ischemia

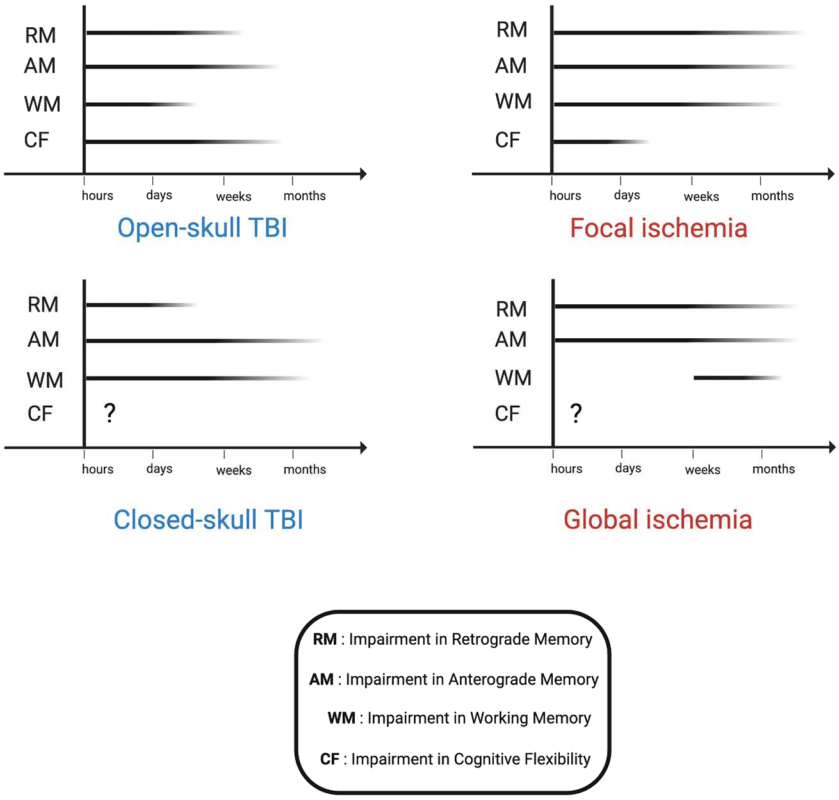

Figure 3 : Patterns of memory impairment across rodent models of traumatic brain injury and brain ischemia

Tableau 1 : Summary of electrophysiological findings

Model	hours	days	weeks	months
Open-skull TBI				
Excitability cortex	↓	↑	↓	→
Excitability hippocampus	↓↑	↑	↑	↑
LTP hippocampus	↓	↓	↓	↓
fMRI	Decrased interhemispheric connectivity Decreased long range connectivity / increased short range connectivity			
Closed-skull TBI				
Excitability cortex	↓	↓	↓	↑
Excitability hippocampus	↑			
LTP hippocampus		↓	↓	
EEG/LFP	**Cortex :** Cortical spreading depression Increased theta-gamma PAC in mPFC			
Focal Ischemia				
Excitability cortex			↓↑	
Excitability hippocampus				
LTP hippocampus		↓	↓	
EEG/LFP	**Cortex :** decreased alpha/beta, increased delta **Hippocampus :** decreased PAC in CA1			
fMRI	**Decreased interhemispheric connectivity**			
Global Ischemia				
Excitability cortex				
Excitability hippocampus		↓	↓	↑
LTP hippocampus	Ischemic LTP		↓	↓
EEG/LFP	**Cortex and hippocampus : Decreased alpha, beta, theta, Increase in delta. Decreased PAC**			

Table 2 : Summary of morphological findings in open-skull TBI

Open-skull TBI	Early	Late>1 months
Cortex		
lesion	Gross examination : Can appear normal Cavity bordered by gliosis [61 62] Axonal damage : Decrease in MAP-2 staining [61]	Increase in cavity size at Y1 [63 62]
perilesional	Neurodegeneration : [67] Cell loss : selective loss of PV+ SOM+ interneurons at W2-W4 [66] Dendritic spines : Drastic decrease at D1 [68] Neuroinflammation : Astrocytosis at D2 [61]	
contralateral	Dendritic spines : decrease at D1 [68] Neurodegeneration : Reported up to D2 [81] D7 [67] but not at W4 [99]	
distant	Dendritic spines : decrease in entorhinal cortex at D1 [68] Cell loss : no evidence at W2 in mPFC with increase in GAD67+ cells [130]	
Hippocampus	Neuroinflammation : Astrocytosis at D1 ipsilateral, at D2 contralateral [61]	
Dentate Gyrus	Cell loss : GABA cells, and mossy cells [78 76] dendritic spines decrease at D1 (bilateral) [68] Neurodegeneration up to D7 (bilateral) [67 81 71] (unilateral) up to M1 [88] and W4 [99] Neurogenesis : up to D3 [406] Aberrant migration until W8 [407]	Cell loss : Decrease in hilar neurons at Y1 [63] in both hemispheres Neurogenesis : Aberrant migration of immature neurons until W8 [88]
Cornu Ammonis 3	Cell loss : GABA cell loss [76] Neurodegeneration up to D7 (bilateral) [67]	
Cornu Ammonis 1	Cell loss : GABA cell loss [77 76]	
Perforant Path		
Mossy Fibers	Mossy fiber sprouting [83]	
Schaffer Collaterals	Damage to SC in CA3 radiatum [81]	
Fimbria	MRI : hemorrhage [89]	
Alveus	MRI : hemorrhage [89]	
Striatum	Neurodegeneration up to D7 (bilateral) [67]	APP axonal swelling up to Y1 [62]
Thalamus	Astrocytosis within W1 [61] Neurodegeneration at D2 [81] and up to D7 [67]	Thalamic calcifications at M1 [63] M2 [62] APP axonal swelling up to M6 [62]
Medial Septum	Cell loss : decrease in ChAT+ at W4 [90] Apoptosis : increase in apoptotic cells up to W1 Loss of tissueat W2 [63]	Increase in tissue loss at Y1 [63]
Nucleus Basalis Meynert		
Cholinergic projections		
Amygdala		
White Matter and Diffuse Axonal Injury	Enlargement of ventricles [93 88 94] Myelin loss [95 96 97]	Enlargement of ventricles and hemispheric volume loss up to Y1[93]
Corpus callosum	Neurodegeneration from D1[67] D2[91] up to D7 [67 91] MRI : hemorrhage [89] dMRI : decreased FA from H3 to D2 ; normal at D7 [408]	Neurodegeneration : APP axonal swelling up to Y1 [62]
Anterior commissure		
Internal capsule	Neurodegeneration up to D7 [67] Pathological DTI metrics at W12 [409]	
Cerebellum	Neurodegeneration up to D7 [67] No degeneration observed up to M1 in [88]	
Hypothalamus	Neurodegeneration [81]	
Brainstem	Not a common feature but observed with craniotomy close to midline Neurodegeneration up to D7 [67]	
Optic structures		

Table 3 : Summary of morphological findings in closed-skull TBI

Closed-skull TBI	Early	Late>1 months
Cortex		
lesion	Gross examination : contusion possible in weight drop[169] / no contusion in Marmarou model [179] Microscopic lesions : predominate in supraventricular cortex (i.e. site of impact) Cell loss : pink shrunken neurons at 24h [169 179]; [182 178]; at W1 [183] at M1 [185] Neurodegeneration (fluorojade) retrosplenial cortex, sensory and motor cortex at D1 D3 [190] Neuroinflammation : at D1 [186 178] at W1 [214] Brain-blood barrier impairment at H6 [178] Vascular damage : pericapillary odema, capillary congestion [179]	Neuroinflammation : at M3 [186] Cell loss at M1 [178 184]
Hippocampus	Astrocytosis [188]	
Dentate gyrus	Cell loss [182] at W1 Degeneration at D3(Fluorojade) [190 191] [(Aminoculpric silver) at W2 [188] No degeneration at D1, D2 and W1 (Fluorojade) [67] W2 [189]	
Cornu ammonis 3	Cell loss [182] at W1 [187] Degeneration at W2 [188]	
Cornu ammonis 1	Cell loss at W1 [187 183] Degeneration at W2 [188]	Cell loss at M1 [184]
Perforant Path		
Mossy Fibers		
Schaffer Collaterals		
Fimbria		
Alveus		
Striatum	Minimal degeneration (Fluorojade) [67]	
Thalamus	No denegeration (Fluorojade) [67] Axonal damage : APP immunoreactivity at M3 [186]	
Medial Septum		
Nucleus Basalis Meynert		
Cholinergic projections		
Amygdala		
White Matter and Diffuse Axonal Injury	Oedema and BBB permeability [410], not observed in [202] Neurodegeneration at W2 [175]	
Corpus callosum	Pericapillary odema and BBB [411] Myelin pathology at W1 [193] Neuroinflammation at W1[193 196] Neurodegeneration (fluorojade) and axonal damage (ß-APP, dephosphorylated neurofilament) at W1 [190 196 67] at W2 [175] Impairment in anterograde (synaptophysin) and retrograde (Fluorogold) transport up to W2 [190] DTI imaging abnormalities at W1 [196]	Neuroinflammation at W6 [193] Myelin pathology at W6 [193]
Anterior commissure		
Internal capsule	Axonal injury : axonal swelling, retraction ball at D1 [179]	
Cerebellum		
Hypothalamus		
Brainstem		
Optic structures		

Table 4 : Summary of morphological findings in focal ischemia

Focal Ischemia	Early	Late>1 months
Cortex		
lesion	Ischemic damage : sensorimotor cortex but also parietal cortex auditory cortex [247] entorhinal cortex [248] Selective neuronal loss with neuroinflammation [253] PFC damage with photothrombotic [250] or ET-1 models [251] [252] Neurodegeneration in contralateral cortex [267]	
Hippocampus	Ischemic damage : [255] [244]	
Dentate gyrus		
Cornu ammonis 3		
Cornu Ammonis 1	Neuronal loss in CA1 [259]	
Perforant Path		
Mossy Fibers		
Schaffer Collaterals		
Fimbria		
Alveus		
Striatum	Ischemic damage : in proximal MCAO (and some distal MCAO models) [256] [249] [254] [255] Selective neuronal loss [257]	
Thalamus	Ischemic damage [244] [255] Decreased thalamic size [250] [264] Neurodegeneration : MEMRI [266], Abeta [269]	
Medial Septum		
Nucleus Basalis Meynert		
Cholinergic projections	Remote lesion [265]	
Amygdala	Ischemic damage [255] [244]	
White Matter and Diffuse Axonal Injury		
Corpus callosum	Neurodegeneration : [267]	
Anterior commissure		
Internal capsule		
Cerebellum		
Hypothalamus	Ischemic damage [244]	
Brainstem		
Optic structures		

Table 5 : Summary of morphological findings in global ischemia

Global Ischemia	Early	Late>1 months
Cortex		
lesion	Ischemic damage : predominates at the junction of arterial territories, as well as in parasagittal regions (veinous ?) [328] Layer specificity : III and V [329 328 324] PFC dendritic architecture [329] Columnar distribution in Rice-Vanucci model [327]	
Hippocampus		
Dentate gyrus	Cell loss [335] Interneuronal loss [337 338] Mossy cells loss [335]	
Cornu ammonis 3	Cell loss [335]	
Cornu Ammonis 1	Delayed neuronal cell death [330 332 331] Mechanism of cell death [333] Alteration of BBB [412]	
Perforant Path		
Mossy Fibers		
Schaffer Collaterals		
Fimbria		
Alveus		
Striatum	Ischemic damage [341 342]	
Thalamus	Ischemic damage [344]	
Medial Septum	Ischemic damage [344]	
Nucleus Basalis Meynert		
Cholinergic projections		
Amygdala	Ischemic damage [344]	
White Matter and Diffuse Axonal Injury	Ischemic damage [322 339 340 342 345]	
Corpus callosum		
Anterior commissure		
Internal capsule		
Cerebellum	Ischemic damage [343]	
Hypothalamus		
Brainstem		
Optic structures		

Table 6 : Summary of behavioral findings in open-skull TBI

Open-skull TBI	Retrograde memory	Anterograde memory	Working memory	Cognitive flexibility
Spatial memory	Impaired in MWM at D2 for task learned 2 hours before trauma [74] Impaired at W2 for tasks learned 1 day or two weeks before trauma. Improved with reminding procedure for two week group [111] No deficit at W1 for task learned one day before injury [99]	Impaired spatial memory in MWM from W2 [100 101] M1 [62 102] M2 [116] M7 [92] Y1 [62] Impaired spatial memory in BM at W1 [104] M1,M2 [103] M3 [105]	Deficit in 8-Arm Radial Maze up to W2 [99] Deficit in paired trials in MWM at W2 [112] Deficit in delayed non match to place test in Tmaze at W1 [114]	Impaired reversal learning at W3 [101]at W8 [115 116]
Object recognition		Impairment in NOR at W1 [106]		
Other				Impaired reversal learning in Touchscreen based visual discrimination at M3 after injury at post natal day 12 [98]
Olfactive memory				
Fear memory	Impaired at W1 with training performed one day before trauma [77]	No impairment in PAT at D10 [100] Impaired in PAT at W3 [101] Impaired in Cued Conditioning at W1 [109]		
Other				
Motor impairment	Tends to recover in the first few days after injury [93 82] with normal swimming speed at M1 after FPI [115] but deficits can be observed at M1 [97 101] and up to Y1 after injury [62]. Increased torsoflexion due to striatal damage at W3 [54]			
Sensorial impairment	Vision	Can in theory be impaired but animals are able to perform visual discrimation task at M3 [98]		
	Whisker	Pain/discomfort upon whisker stimulation up to W8 [122]		
	Olfaction	Impaired olfaction at D4 after olfactory bulb impact [123]		
Anxiety and depressive like behaviors	Impairment in Forced swim Test at D4 [116] at W3[54], in Tail Suspension Test at W3 [101] Anxiety like behavior in the elevated plus maze at D2 [116]			

Table 7 : Summary of behavioral findings in closed-skull TBI

Closed-skull TBI	Retrograde memory	Anterograde memory	Working memory	Cognitive flexibility
Spatial memory	MWM : Decreased at D2 after injury [213] No evidence [36]	In MWM : Impaired at W1 [183 198 214] at W2-3 [199 200] at M1 [185 184]up to M3 [202 186]. No deficit at W5 [203] and M2 [204] In Y Maze : impaired up to M3 [186]	swim T-maze : deficit one month after injury [207] MWM : impaired at M1 but not at M2 [184] 8-Arm radial maze : no deficit after W6 [204]	
Object recognition		Deficits at D3 [211] and up to W2 [189 208] No deficits at D1,D2 [209]at W7 [210]		
Other		Touchscreen : No deficit in Location Discrimination Task [205]		
Olfactive memory		exploration deficit at D3 post conditioning with predator scent [204]		
Fear memory	Deficit in PAT [212]	Deficit in PAT at D2 [206 196] and at M1 [207] Increased freezing during cued conditioning [204]		
Other				
Motor impairment	Motor deficits which tend to recover in the first few days [177 209 214 175] or weeks [197 186] after trauma. However no return to baseline values at M1 [199]. No difference in swim-speed in the MWM at W1-W3 [214 201 200]			
Sensorial impairment	Vision	Vision impairment [197]. Animals able to perform location discrimation task on touchscreen in the first few days after injury [205]		
	Whisker	Deficits in whisker-evoked forepaw placement up to W6, more aversive responses upon whisker stimulationat W3 [210]		
	Olfaction	No impairment in olfactive memory [204]		
	Auditory	Tinnitus-like auditory deficits [203]		
Anxiety and depressive like behaviors	Forced Swim Test : Depressive-like behavior at D3 [200]at W1 and M3 [207]. No deficit early days after injury [36]. Elevated-plus maze : no anixety like behavior in the early days after injury [36] but observed at W5 [203]			

Table 8 : Summary of behavioral findings in focal ischemia

Focal ischemia	Retrograde memory	Anterograde memory	Working memory	Cognitive flexibility
Spatial memory	MWM : Deficits at W8 [275]	MWM : impaired learningat M1 [270], not found in [272] [260] [280] [274] at W2 ; impaired at W8 [271] Barnes Maze : decreased performance at W2 [258] Oject Location Task : not impaired at W1 but impaired at M1 [250]	Radial Arm Maze : deficit at M1,M2 [277] Y-maze : no deficit at D3 [273] T-maze : no deficit at W3 [247]	Plus-maze : Deficit in attention set-shift at d8 [252]
Object recognition		No impairment at W1 and M1 [250]		
Other		Touchscreen visual discrimination : deficit at W1 [285]		Touchscreen visual discrimination : no deficit at M1 [278]
Olfactive memory		Deficit in social transmission of food preference task at W2 [258]		Deficit in atttention set shift at D10 [251]
Fear memory	PAT : deficit at W1 [276] at W3 [275]	Impariment in PAT at W1 [259] [273] [280] at W7 [271] No deficit in PAT at W2 [274]		
Other				
Motor impairment	Contralateral motor deficits [279] [273] [260]with return to sham levels within weeks [270] [266] [260]. Deficits in fine motor tasks at W3 [283] [274] at W8-W9 [264] [284] [263]			
Sensorial impairment	Vision	Normal performance in cued version of MWM [270] but impaired in visual discrimination tasks with highly similar images [285]		
	Whisker	?		
	Olfaction	Deficit in social transmission of food preference task at W2 [258]		
Anxiety and depressive like behaviors	Motor hyperactivity following right but no left MCAO [287] [288] Anxiety-like behavior after left MCAO at W9 [288]; impaired at W1after left mPFC stroke [293] but not after bilateral photothrombotic mPFC stroke at W1 and M1 [250] Depressive-like behavior after left MCAO at W2-W3 [289] and right MCAO [290] [291] and at W2 after left mPFC stroke [293]			

Table 9 : Summary of behavioral findings in global ischemia

Global ischemia	Retrograde memory	Anterograde memory	Working memory	Cognitive flexibility
Spatial memory	MWM : Deficits at W7 [353]	MWM : Deficits at W2 [351], at W3 [352], at W7 [353]; no deficits in BCAS at M1 [339] [354]; Deficits at W3 [355] at W6 [356]at M2+M4 [357] Barnes Maze : deficit at W1 [323] Hole-board test : deficit at W1 [363]	*Late onset* Radial Arm Maze : deficit at W8-W15 [357]; at M1 [354] [340] ; at M16 [364] Y-maze : at M1 [339] [325]; at M2 [325]; at M3 [325] T-maze : deficit at W1 [362] Hole-board test : deficit at W1-W2 [363]	
Object recognition		Impaired at M2 and M3 [325]		
Other				
Olfactive memory				
Fear memory		Contextual fear conditioning deficit at W1 [323] [359] at W4 [359]		
Other				
Motor impairment	Increased locomotor activity [341] [359] but normal in [356] [340] Normal swimming speed in MWM in [355] [339] Decreased forepaw activity [341] Gait deficits [325] Severe akinesia [341]			
Sensorial impairment	Vision	Altered pupillary light reflex [349] influencing performance in MWM [365] but rats able to perform in cued MWM [354] [357]		
	Whisker	?		
	Olfaction	?		
Anxiety and depressive like behaviors	Decreased anxiety in at D4 [366] at D5 [367] Depressive like-behavior in Forced Swim Test/Tail Suspension Test at M1 [368] in Tail Suspension Test at D3 [366], no evidence in Forced Swim Test at W1 [340]			

Table 10 : Summary of physiological findings in open-skull TBI

Open-Skull TBI	In vitro	In vivo	Proposed mechanisms
Cortex	Decrease in slow-cortical oscillations [138]	Increased slow wave Decreased fastwave [60] High Frequency Oscillations [137]	
lesion	Hypoactivity [124] followed by hyperactivity (observed in layer V) [125] [124]	Hypoactivity which predominates in upper layers at D1 [413] with normalisation of activity at W12 [127]	Hypoactivity : cortical spreading depression Hyperactivity : Loss of GABAergic interneurons
perilesional	Hyperexcitability in layer V [66]		Interneuronal loss or dysfunction [66]
contraleral	Hyperexcitability at D1-D2 [131]	Hyperexcitability at D3 and W4 [132]	Loss of interhemispheric inhibition
distant			
Hippocampus			
Dentate gyrus	Increased excitability in mossy cells at D1 [139]at D7 [140] Decreased excitability of granule cells at D3 [146]	Increased excitability in granule cells at W1 [64] at W8-W12 [143]	Intrinsic excitability (decrease Ih in mossy cells [139]) Recurrent excitation from mossy fibers [143] Decrease in synaptic inhibition [143] Dendritic degeneration [146]
Cornu ammonis 3	Increased excitabilityat W1 [142]	?	Impairment of dente gyrus filtering [142]
Cornu ammonis 1	Decreased excitability at D2 [147] Increased excitability at W1, normal at W8 [141]	Increased excitability at H2-H3 [148] Increased excitability at D2 [149] Decrease in broadband activity at W1 [157]	Intrinsic excitability (decrease in Ia current) [141]
LTP Perforant Path-Granule Cells	Decrease in LTP at D7 [150] [151]	?	
LTP Mossy Cells-Granule Cells	?	?	
LTP Dentate Gyrus-Cornu Ammonis 3	?	?	?
LTP Cornu Ammonis 3-Cornu Ammonis 1	Decreased LTP, increased LTD at D2 [152] [147] Partial recovery at W1 [156] Decreased LTP at W1 [77] [154] Deficit in LTP maintenance at W8 [155] (note no difference at D6)	Decreased LTP at H2-H3 [148] at D2,W1, W2 [149] at H4,D2 [153]	Decrease in number of synaptic contacts, and alterations of morphology [154] Excitatory failure : NMDA and AMPA receptor dysfunction [154] CA 1 deafferentation [156] but no difference in fiber volley amplitude [414154] Pathological LTP [147] but not salvageable [154]
fMRI	/	Decrease long-range connectivity Increase short-range connectivity [136]	
PAC	?	?	/

Table 11 : Summary of physiological findings in closed-skull TBI

Closed-skull TBI	In vitro	In vivo	Proposed mechanisms
Cortex		Cortical spreading depression [219]	
lesion		Hypoexcitability but increased firing rate in layer IV and Va at D1 [215] Hypoexcitability across all layers including supragranular layers at W2 [415] Hyperexcitability in supragranular layers, normal in infragranular layers at W8 [210]	Activation of parvalbumin positive interneurons [216]
Hippocampus			
Dentate Gyrus			
Cornu Ammonis 3			
Cornu Ammonis 1	Increased excitablity at H2 and D1, but not at D3 [187]	Decreased SWR [217]	
LTP Perforant Path-Granule Cells	Impaired LTP at D2 [206]		
LTP Mossy Cells-Granule Cells			
LTP Dentate Gyrus-Cornu Ammonis 3			
LTP Cornu Ammonis 3-Cornu Ammonis 1	Impaired LTP [188] at W2[189]		
fMRI	?	?	
PAC	?	Increased theta-gamma PAC in mPFC [217]	

Table 12 : Summary of physiological findings in focal ischemia

Focal ischemia	In vitro	In vivo	Proposed mechanisms
Cortex			
lesion		Decreased alpha power/beta power ratio Increased delta power [303] [304]	
perilesional	Increased excitability at D7 [294], Decrease paired-pulse inhibition at D7 [296] Increased LTP at D7 [294] Decreased excitability at D7 [295]	Periinfarct DC shift [309]	Hyperexcitability : decreased inhibition [296] Decrease d excitability : reuptake of GABA by astrocytes [223]
contraleral	Decreased paired-pulse inhibition at D7 [297]	Contralateral hemisphere : increase in delta power followed by increase in beta power [307]	Decreased inhibitory output from the injured cortex [297]
distant			
Hippocampus			
Dentate Gyrus			
Cornu Ammnonis 3			
Cornu Ammonis 1			
LTP Perforant Path-Granule Cells			
LTP Mossy Cells-Granule Cells			
LTP Dentate Gyrus-Cornu Ammonis 3			
Ltp Cornu Ammonis 3-Cornu Ammonis 1	Decreased LTP at D3 [310] at M1 [248]		
fMRI			
PAC		Decreased PAC in CA1 immediately after ischemia [311]	

Table 13 : Summary of physiological findings in global ischemia

Global Ischemia	In vitro	In vivo	Proposed mechanisms
Cortex			
		80 to 100% drop in EEG signal [369] [370] Increased Delta activity, decreased alpha, beta and theta [370] Decreased superficial theta at D1 [371]	
Hippocampus			
Dentate Gyrus	Decreased activity at D10 and M1 (irradiated animals) [387]	Decreased activity in the first days after injury [372]	
Cornu Ammonis 3	Hyperexcitability M2 to M4 after ischemia [378]		
Cornu Ammonis 1	Decreased activity at D10 and M1 (irradiated animals) [387]	Decreased theta power at D1 [371] Increase in Delta power decrease in alpha, beta and theta power [370] Increased activity in the first hours after injury [376] Decreased activity in the first days after injury [372] at W1[377]	Loss of CA1 pyramidal cells ? [371]
LTP Perforant Path-Granule Cells			
LTP Mossy Cells-Granule Cells			
LTP Dentate Gyrus-Cornu Ammonis 3			
LTP Cornu Ammonis 3-Cornu Ammonis 1	Ischemic LTP under hypoxic conditions [379] [380] Reversal of ischemic LTP with low-frequency stimulation [383] Disturbed LTP at W8 after 4VO [356] No impairment but increase in PPF at W1 [323]	LTP in some neurons [382]at H7 [381] LTD in other neurons [382] Impaired LTP at W2 after 2VO [384] and 4VO [363].	Activation of NMDA receptors [379]
fMRI			
PAC		Decreased PAC [352] as well as general partial directed coherence information transfer between CA3 and CA1 [351], and long-range synchrony [373]	